

## ESTHETICS IN ANTERIOR IMPLANT PROSTHETICS

Gregori Kurtzman<sup>1</sup> Lee Silverstein<sup>2</sup> Lanka Mahesh<sup>3</sup>Narayan TV.<sup>4</sup> Udatta Kher<sup>5</sup> David Kurtzman<sup>6</sup>

<sup>1&6</sup>Private practice Maryland, USA.

<sup>2</sup>Private practice Georgia, USA.

<sup>3</sup>Private practice New Delhi, India.

<sup>4</sup>Oral Pathologist and Implant Dentistry Bengaluru, India.

<sup>5</sup>Private practice Mumbai, India.

**Correspondence:** Lanka Mahesh B.D.S,M.B.A,D.H.A,D.H.H.M M.S (Implant Dentistry) UCLA,USA M.S (Implant Dentistry) CUFD Thailand Diplomate ICOI (USA) F.I.C.O.I ( USA),F.I.S.O.I Email : drlanka.mahesh@gmail.com

### ABSTRACT

There are several factors to consider while a tooth is to be replaced with an implant in the anterior region and achieving an esthetic result is even more challenging. We must evaluate numerous criteria to achieve the optimal esthetics. This article details a technique to replicate the soft tissue support and thus replicate the gingival margin position developed with the provisional restoration to achieve high functional and esthetic results.

**Keywords:** anterior, implant, esthetics

### INTRODUCTION

Anterior Implant Esthetics – three words that imply numerous and treacherous pitfalls and strike fear into the hearts of restorative dentists. Among the challenges is the accurate and predictable communication of proper final tissue contours to the dental laboratory.<sup>1,2</sup> Only with proper communication of the gingival architecture, can the laboratory provide a natural appearing restoration. Anatomical and esthetic gingival contours make or break the anterior case. A natural, healthy gingival architecture that mimics and blends with natural dentition is not only highly desirable but – in most cases – attainable. With proper placement of the implant body, adequate soft tissue and a temporary restoration that guides and shapes the tissue into lifelike contours an implant restoration in the anterior region can appear natural and beautiful.<sup>3,4,5</sup>

Placement of the fixture – as referenced in numerous articles – is facilitated by good communication between the restorative dentist and the surgeon and is achieved through, accurate surgical guides.<sup>5</sup> Proper orientation of the fixture is required in the mesio-distal, buccal-lingual and occluso-gingival planes. When deficiencies in the hard and/or soft tissue prevent ideal placement of the fixtures then allografting and autografting techniques may be utilized to supply abundant soft tissue with which to create esthetic contours.

Once the implant is placed and the tissue has healed, sculpting of interproximal papillae and the buccal crescent of gingiva are accomplished with sequential fixed temporaries.<sup>6,7</sup> Step wise addition of temporary material manipulates tissues to place and creates proper esthetic

contours. Once accomplished, these contours must be accurately and predictably conveyed to the laboratory.

Enter the ‘Custom Impression Coping’. By copying the final contours of the fixed, esthetic temporary restoration to an impression coping, gingival tissue is supported in the correct anatomical position during the impression procedure. This prevents tissue collapse during the impression phase and allows an accurate communication of the position of the soft tissue.

### CASE REPORT

A 55 year old female was sent by her surgeon to treatment plan an implant in the edentulous area of tooth #9 (upper left central incisor). The space had been occupied by an ill fitting and unaesthetic bonded pontic. The patient desired more natural and harmonious smile.

A surgical guide created by the restorative dentist in concert with the surgeon was used to place the implant in proper position. Healing took place over six months at which time the fully integrated fixture was surgically exposed by removing a “plug” of tissue with a surgical trephine. A 5mm healing abutment was placed and the patient was immediately sent to the restorative dentist to begin tissue manipulation with the temporary restoration.

A screw retained temporary abutment (Biomet 3i, Palm Beach Gardens, FL) was air abraded using 50 micron alumina oxide (Danville Engineering, San Ramon, CA). The roughened temporary abutment was then coated with a bonding agent (Prime & Bond, Dentsply Caulk, Milford, DE) and a hybrid composite resin (Esthet-X, Dentsply Caulk, Milford, DE) was added to the screw retained

temporary abutment head to shape the tissue to the desired gingival contours. The supra-gingival portion was created intraorally with the temporary abutment cylinder screwed into place. Once this was formed, the subgingival portion was created extraorally in the lab.

Over a period of several weeks, the temporary was modified by adding and subtracting composite subgingivally until it reached final esthetic contour and the surrounding tissues were in proper position. When these tissues were pink, firm, stable and healthy, an open impression tray was fabricated (Triad Transheet, Dentsply Prosthetics, York, PA). (Figure 1 and 2)

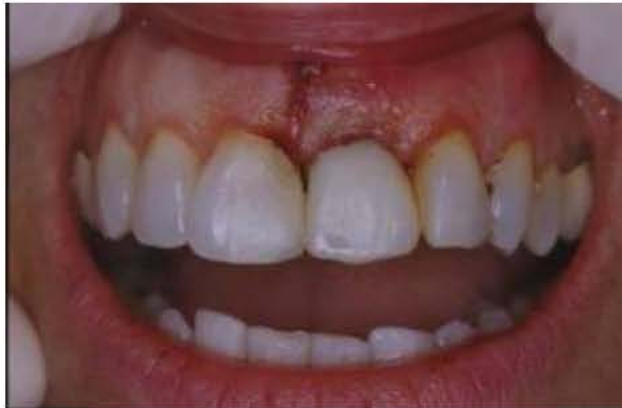

Figure 1: Screw retained implant provisional restoration at site 9, placed at time of implant uncovering.

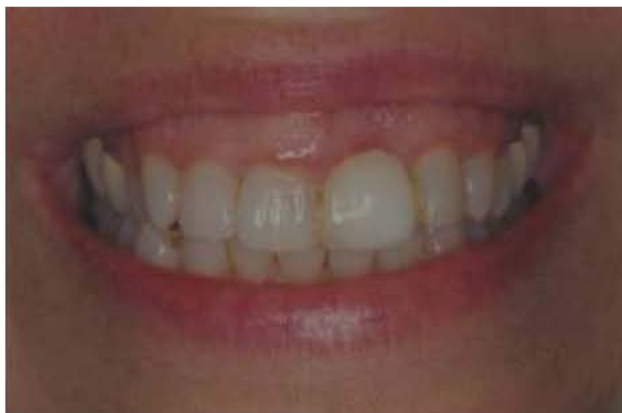

Figure 2: Screw retained provisional following soft tissue healing and development of soft tissue contours and emergence profile.

It has been noted and documented that once the temporary restoration is removed, the gingival tissues tend to collapse and “slump” rather rapidly over the implant platform. Even a relatively fast impression with a standard impression coping will result in an inaccurate model of proper esthetic gingival contour. While some labs may be able to compensate for this by manipulation of the models, it is unpredictable and seldom as esthetically correct as the

temporary restoration. The custom impression coping solves this problem.

Since the gingival portion of the temporary supports the tissue, this is the area that must be copied. The temporary restoration was secured to an appropriate lab analogue and the tissue surface was lubricated (Dentsply Triad model release agent). A quick set lab stone (Grey Set FS. –Dental Mfg. Corp., Newark, NJ) was mixed using a vibrator and placed into a container. The lab analog and attached temporary restoration were inserted to the height of contour of the restoration and allowed to set.

Once the stone was completely set, the temporary was unscrewed from the analogue and removed from the stone. The analogue remained at the bottom of a smooth, accurate impression of the contours of the temporary restoration making a mold to create the custom impression coping. (Figure 3)

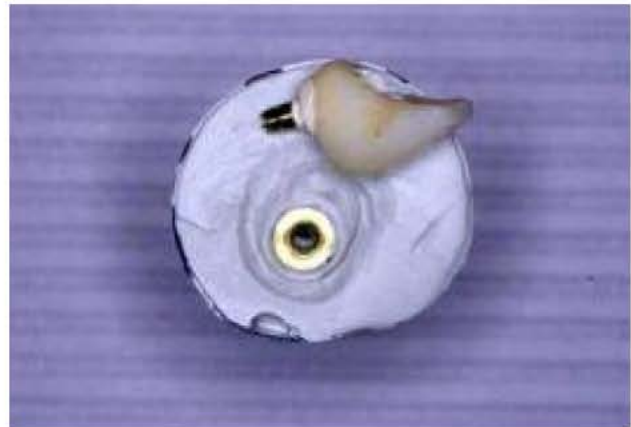

Figure 3: Screw retained provisional removed from the analog within the matrix demonstrating the matrix replicating the emergence profile achieved by the provisional.

A “stock” open tray impression coping was next used to create the custom impression coping. To aid in the adhesion of the custom material to the coping, the end of the coping facing the implant analogue, but avoiding the portion in contact with the analogs platform, was roughed up with a diamond (Brasseler USA, Savannah, GA) and air abraded as previously described to roughen the temporary abutment. The stone impression was lubricated with model release agent and the impression coping, after being coated with bonding agent (Prime & Bond), was screwed onto the implant lab analogue embedded in the stone mold. (Figure 4) Flowable composite (Flow-it, Pentron Clinical Technologies, Wallingford, CT) was carefully injected around the coping into the stone mold and light cured in layers to ensure complete curing of the resin within the mold. (Figure 5) Alternatively, Duralay self cure resin (Reliance Dental, Worth, IL) may be used in place of the flowable composite resin.





Figure 4: Custom matrix with open tray impression head placed on the analog.

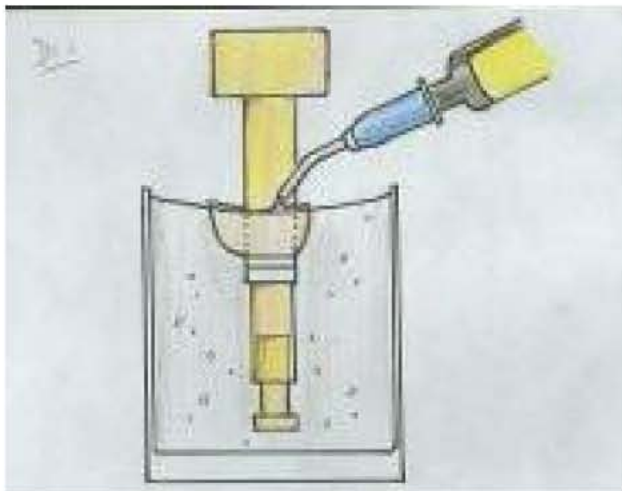


Figure 5: Illustration demonstrating fabrication of the custom impression coping.

Once cured, the coping was unscrewed from the implant analogue and removed from the stone mold. The perfect replica of the tissue portion of the temporary was then wiped with alcohol to remove uncured resin in the air inhibited layer. This replica – the custom impression coping – was ready for the final impression. (Figure 6)



Figure 6: Completed custom impression coping ready for intraoral use.

After orienting intraorally on the implant after removal of the temporary restoration, the custom impression coping was fixated to the implant via a long impression pin, supporting the soft tissue as the temporary restoration had previously. The tissues, properly supported, regained the desired contours created by the temporary. An open tray impression using a custom tray (Triad Transheet, Dentsply Prosthetics, York, PA) previously fabricated was filled with a polyether impression material (Impregum, 3M/ESPE, St. Paul, MN) was taken and sent to the lab along with an interocclusal bite record using a rigid PVS bite material (Correct Bite, Pentron Clinical Technologies, Wallingford, CT) and an opposing model. (Figure 7, 8 and 9) Additionally an impression of the temporaries was taken intraorally to aid the lab in seeing the desired crown contours and a stick bite to further define the incisal plane and midline.

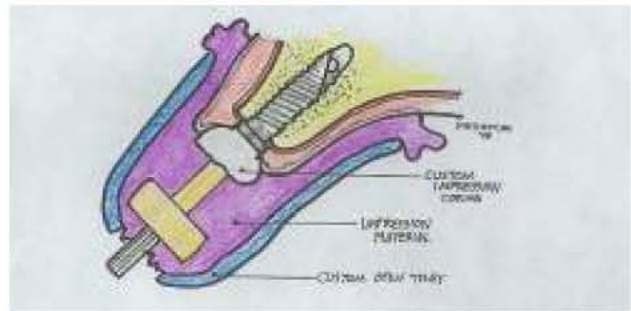


Figure 7: Illustration demonstrating how the custom impression coping is utilized.

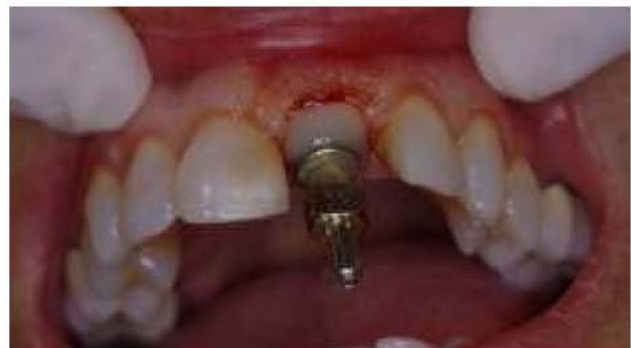

Figure 8: Custom impression coping fixated intraorally supporting the soft tissue.



Figure 9: Open tray impression with custom open tray impression head embedded within.

The laboratory using the open tray impression with the custom impression coping was able to fabricate a soft tissue model. This replicates sulcus dimensions and gingival margin position as developed intraorally permitting the lab to design a restoration that mimics what has been developed intraorally and provides natural esthetics.

On delivery, the restoration fit precisely and harmoniously with the natural and esthetic contours of the gingival. The implant supported restoration is indistinguishable from the adjacent teeth and is a functional and esthetic success. The guess work as to where the tissue will position after restoration placement is eliminated. (Figure 10)

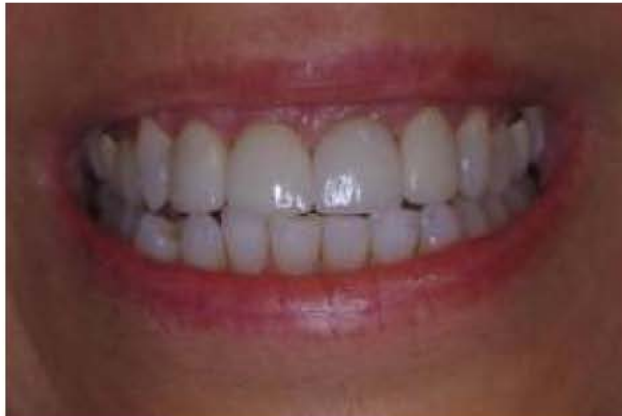

Figure 10: Final restoration showing good soft tissue support and emergence profile replicating what was achieved with the provisional.

### Conclusion

The key to esthetic results with implant fixed restorations is communication of the soft tissue position to the laboratory. We work hard to develop the position of the gingival margin and the emergence profile but when impressions are captured the soft tissue changes position. Tissue collapse occurs as soon as the provisional restoration is removed from the implant fixture.

The methods described herein, details a technique to replicate the soft tissue support and thus replicate the gingival margin position developed with the provisional restoration. Thus, the final restoration provides the esthetic results both the practitioner and patient have worked to develop in the provisional phase.

### REFERENCES

1. Sava CN, Kamposiora P, Papavasiliou G, Orfanou AV. :Intrasurgical implant position transfer and interim restoration placement. *J Prosthodont.* 2008 Dec;17(8):648-53. Epub 2008 Sep 16.
2. Shor A, Schuler R, Goto Y. : Indirect implant-supported fixed provisional restoration in the esthetic zone: fabrication technique and treatment workflow. *J Esthet Restor Dent.* 2008;20(2):82-95; discussion 96-7.
3. Neale D, Chee WW. Development of implant soft tissue emergence profile: a technique.

*J Prosthet Dent.* 1994 Apr;71(4):364-8.

4. Buskin R, Salinas TJ. : Transferring emergence profile created from the provisional to the definitive restoration. *Pract Periodontics Aesthet Dent.* 1998 Nov-Dec;10(9):1171-9; quiz 1180.

5. Elian N, Tabourian G, Jalbout ZN, Classi A, Cho SC, Froum S, Tamow DP. : Accurate transfer of peri-implant soft tissue emergence profile from the provisional crown to the final prosthesis using an emergence profile cast. *J Esthet Restor Dent.* 2007;19(6):306-14; discussion 315.

6. Biggs WF, Litvak AL Jr. : Immediate provisional restorations to aid in gingival healing and optimal contours for implant patients. *J Prosthet Dent.* 2001 Aug;86(2):177-80.

7. Davarpanah M, Martinez H, Celletti R, Tecucianu JF. : Three-stage approach to aesthetic implant restoration: emergence profile concept. *Pract Proced Aesthet Dent.* 2001 Nov-Dec;13(9):761-7; quiz 768, 721-2.

Source of Support : Nil, Conflict of Interest ; Nil