

Common errors in impressions and their rectification

DR. GREGORI M. KURTZMAN, DR. LANKA MAHESH AND HOWARD E. STRASSLER

ABSTRACT

Precise impression taking techniques are critical to indirect restorative success. By ensuring that a concise protocol is implemented for during the impression capture phase, clinicians can predictably deliver optimal results. Common complications that may arise during impression taking include inaccurate marginal detail, bubbles, tears, pits, and voids. Proceeding with impression taking when such damage is evident will reduce the accuracy of restorative fit and integrity. This article discusses potential concerns during impression capture and addresses approaches to improve the overall quality of impressions taken.

LEARNING OBJECTIVES

This article discusses common complications that arise during impression taking and addresses potential solutions for this critical phase of restorative treatment. Upon reading this article, the reader should:

- Understand the necessary protocol for precise impression capture
- Recognize potential pitfalls that may arise during impression taking.

Impression fabrication is the most critical and technique-sensitive step in the fabrication of fixed prosthetics. It can also be the most frustrating stage, both to the clinician and the laboratory technician. Clinicians must take care to identify and correct potential complications that will affect the prosthetics fabricated from the impressions.

INADEQUATE MARGINAL DETAIL

The primary complaint laboratory technicians have with the impressions they receive daily is inadequate marginal detail. Marginal detail is the most critical aspect of the impression. Failure to capture the true details of the margin of the preparation will result in open margins and inadequate prosthetic fit. Voids at the margins are the result of either insufficient retraction or fluid accumulation that

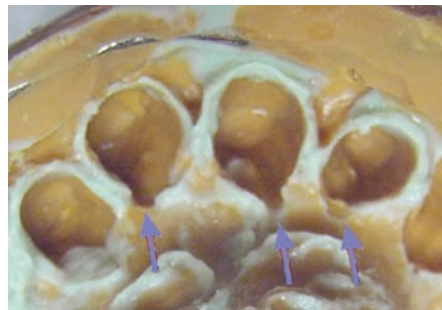

FIG 1A: Impression demonstrates the appearance of marginal voids (arrows)

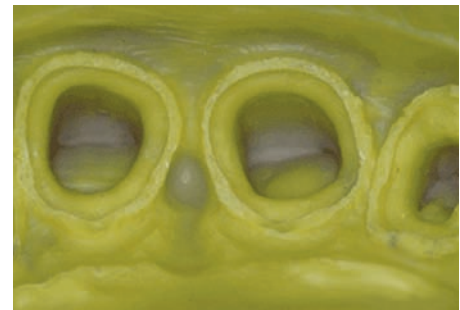


FIG 1B: Appearance of an impression with accurate marginal detail

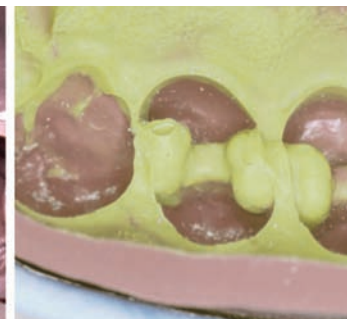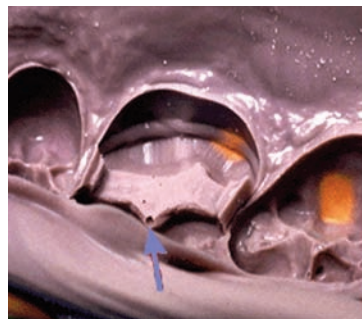


FIG 2: A bubble is located on the internal detail of the impression of the preparation (blue arrow)

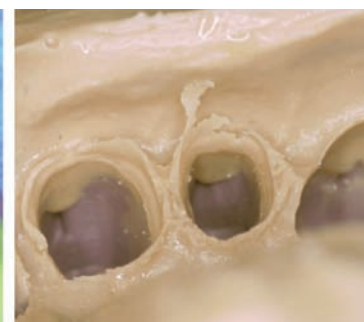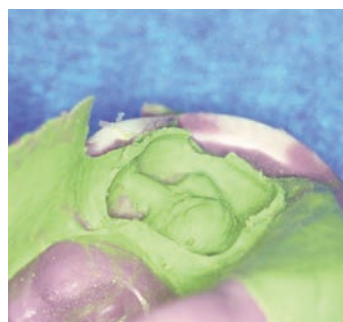


FIG 3: The syringe material following development of a tear at the margin

prevented the impression material from flowing around the margin. This can be avoided by using improved retraction methods such as syringeable hemostatics, bipolar tissue management or Comprecaps (Figure 1).

INTERNAL BUBBLES

Internal bubbles occur as a result of either fluid accumulation (when larger and less sharp in definition) or air entrapment (when

small and well defined) (Figure 2). Bubbles on the margins of the preparations can negatively affect the fit of the prosthetics. If the bubbles occur on the internal line angles of inlay and onlay preparations due to fluid accumulation, a substandard fit will be developed. If they occur due to air entrapment, the fit of the restoration will not be compromised. Bubbles that occur as a result of fluid accumulation may be large enough to affect

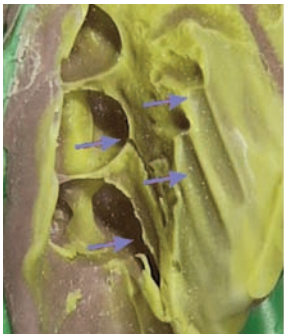


FIG 4: Drags appear as rounded depressions in the impression material

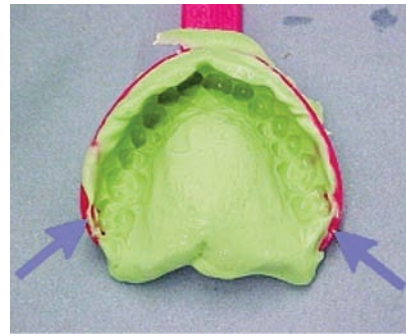
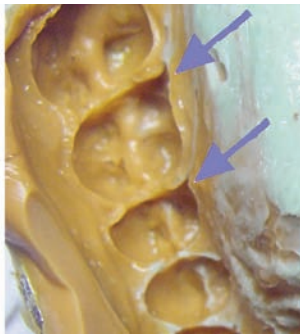

FIG 5: Use of too small an impression tray leads to contact with the tray borders and the teeth (arrows)

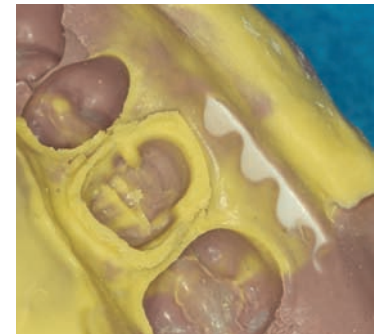


FIG 6: Contact of the tray with the soft tissue may cause potential tray distortion (arrows)

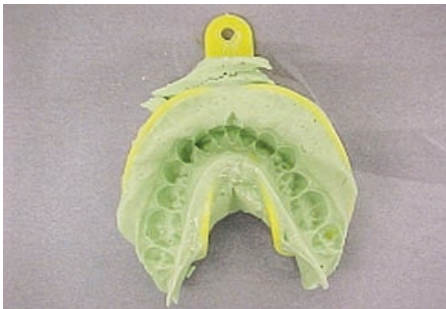

FIG 7: The impression tray has not been inserted far enough posterior to capture the details of the most distal teeth. Note: Excess material was evident in the anterior region due to poor tray placement

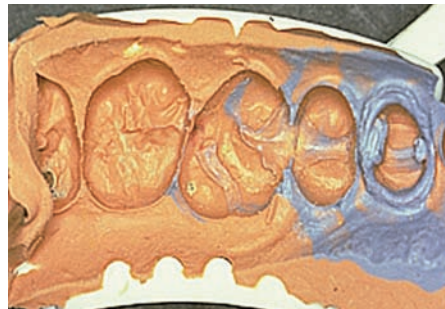

FIG 8: Appearance of an impression following inadequate capture of the teeth surrounding the tooth to be restored

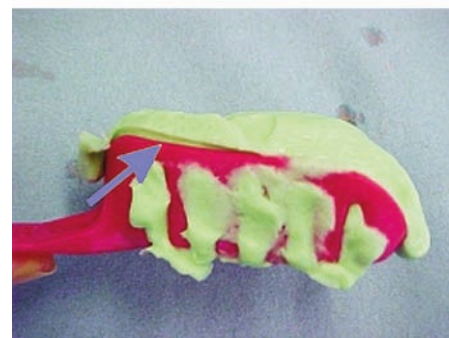
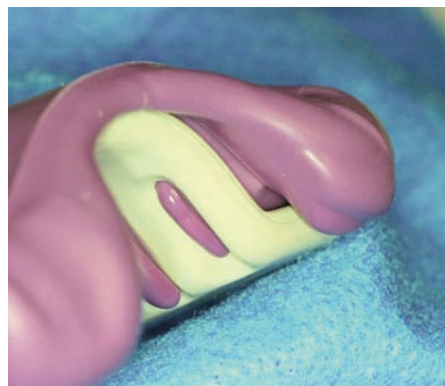

FIG 9: Appearance of an inaccurate impression due to separation of the impression material from the tray (arrow)

the long-term success of the luting agent, which must now fill a wider space. The prosthetic material may also be thinner than recommended. This can be more critical when using all-ceramic materials, as they require minimum thickness to perform as expected. Use of a wash impression is difficult in a completed inlay/onlay impression, as complete seating can be complicated, leading to either a "stepped" or distorted impression. In these cases, it is more prudent to take a new impression and be assured of accurate detail capture. While the cause of large, internal, ill-defined areas in these preparations is usually fluid accumulation, air entrapment may also be a factor in narrow, deep preparations. These errors may be avoided by thorough flushing and drying of the preparation prior to impression taking. Placing a curved intra-oral impression tip into the deepest part of the preparation floor and extruding a light body polyvinylsiloxane (PVS) material, making sure to keep the tip in the material as it is expressed, will force air out of the preparation decreasing entrapment. If an air bubble remains on the cast after the impression is

poured, a corresponding void will be created in the prosthetic material.

MARGINAL TEARS

Marginal tears usually occur when a syringable material with insufficient tear strength is used (Figure 3). Tear strength will vary from manufacturer to manufacturer and between viscosities. These deformities can result when using a syringeable PVS in a thin deep sulcus. Removal of the impression prior to complete setting of the syringable material may also cause marginal tearing. Prior to retaking the impression, any remnants of the original impression material must be removed from the sulcus. Additional tissue retraction may be indicated to widen the sulcus to facilitate use of a thicker syringable material. Switching to a more viscous syringable material may further prevent development of another tear. Syringeable hemostatic materials can be used to limit the amount of fluid evident in the treatment area, and the patient can be instructed to occlude into a cotton device for several minutes, thereby physically pushing the tissue away from the tooth and forcing the hemostatic deeper into the tissues.^{4,5}

DRAGS AND PULLS

A common complication encountered when using more viscous impression materials (i.e., putty or heavy body materials) is drags and pulls. A drag results when long, rounded depressions that resemble the cuspal edges of the teeth are left in the impression material upon insertion of the tray (Figure 4). Whereas, a pull (also referred to as a fold) results when the material creates a fold, usually at the gingival aspect. These deformities can both result from:

- Teeth rebounding off the tray and sliding

prosthodontic section

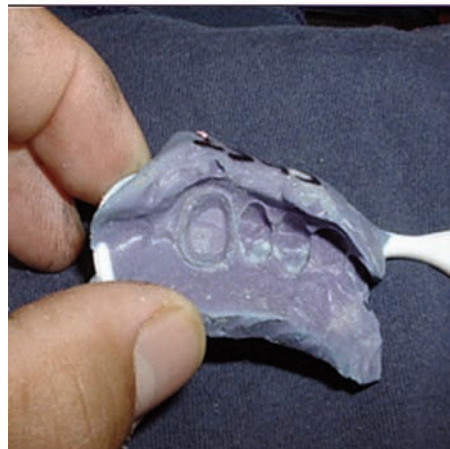

FIG 10: Distortion of the dual arch can occur from contact with the tray during set of the material or inadequate stiffness of the set material

into position.

- Impression material beyond its working time (no longer in its most fluid state).
- Failure of the impression material to adapt to the teeth.
- Exceeding working time of the material prior to intraoral insertion.
- Insertion of the tray in one motion.

Drags and pulls can be avoided by using a less viscous material either syringed around the teeth or placed over the more viscous material in the tray prior to insertion. Correction of a pull in the impression can be accomplished by removal of the interproximal impression material so the impression can be reinserted without interference. A syringable impression material (light or extra-light) should be placed over the entire impression, and the depressions should be filled where the teeth are. The impression can then be reinserted intraorally. Drags, on the other hand often are not correctable by

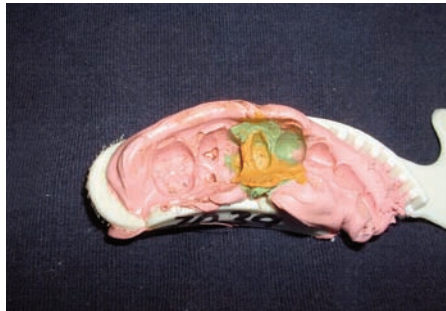


FIG 11: Inadequate application of syringeable material taken as a two part impression leading to a "step" in the material

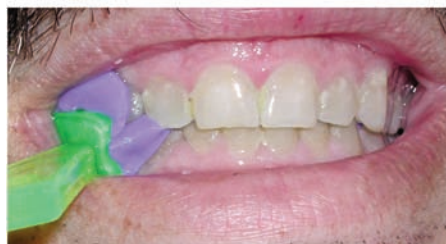
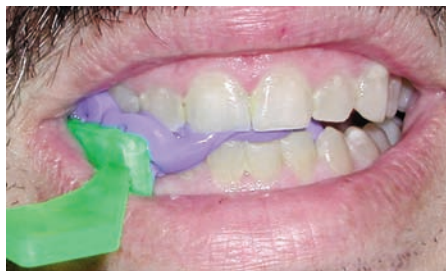
FIG 12: Inadequate occlusal intercuspation during impression with a dual arch tray. Note the open bite on the left side

adding additional material, as they may have caused distortion of the tray. Avoiding contact between the tray and the teeth will help avoid these deformations.

TRAY SELECTION

Tray selection is important to capture the needed area without distortion and provide the needed details.^{6,7} The tray, either a dual arch tray (also known as a bite impression tray) or stock single arch tray, should be large enough to encompass all the teeth without contacting the soft tissue (Figure 5). The completed impression should not demonstrate any show through of the tray. Show-through indicates that the tray used was either positioned improperly or the tray was too small (Figure 6).

When using stock full arch trays it is important to select a tray that is long enough to capture the entire arch from the hamular notches or retromolar pads to the most ante-

rior aspect of the buccal vestibule. In addition, the width of the selected tray is also important. A tray that is too narrow may prevent adequate seating of the tray leading to missing of needed arch detail (Figure 7). Stock trays are provided in basic sizes that may not fit all patients seen in the practice. Metal trays may be bent to widen them in the posterior, but modifications to the anterior of the tray can be difficult. Plastic stock trays are easier to modify. An alcohol torch may be used to heat the plastic tray and the flanges readapted to fit the specific patient. Different companies provide different arch shapes, and it may be advisable to stock several different brands of each size tray. When using quadrant or dual arch trays, it is important to capture at least one full tooth (or the equivalent space) both mesial and distal to the tooth to be restored. Failure to provide this in the impression may make it difficult for the laboratory to properly mount the casts and achieve an accurate occlusion (Figure 8).

SEPARATION FROM THE TRAY

Separation of the impression material from the tray may not be obvious until the restoration is returned and tried in (Figure 9). This deformity may be overlooked when using trays with slots and holes to lock the impression material. Tray adhesive should be used with all impressions to help eliminate impression separation from the tray.⁸ Roughen, create holes for mechanical retention, and clean inner surface of tray with alcohol before applying adhesive. Each impression material's chemistry is different so it is advised that the clinician use the tray adhesive from the same manufacturer as their impression material. Allow the adhesive to dry prior to applying the impression material. The adhesive can be applied at the beginning of the appointment and will then be dry and ready when it is time to take the impression.

TRAY DISTORTION

Trays can distort when they come in contact with the teeth or tissue. Distortion of the tray is more common with dual arch trays due to their more flexible nature as the patient occludes. This distortion can cause either a widened cast tooth when the impression material is stiff enough to resist spring back or an elongated cast tooth if impression spring back does occur (Figures 10). Proper selection of a tray that does not contact the teeth and is rigid enough to resist distortion is crit-

ical. When using triple trays, it is advisable to use a rigid setting PVS material (e.g., a bite registration material) as the bulk of the impression to provide a stable impression.⁹ Two-phase impressions can be used to create a custom format using the triple tray. The preliminary impression creates a rigid base that will provide hydraulic pressure to force the syringeable material in and around the preparations. Trimming the interproximal material from the preliminary impression can aid in seating the wash impression.

INADEQUATE SYRINGE MATERIAL

A "stepped" impression may result when using a two-phase impression technique and insufficient syringeable material has been placed (Figure 11). The result will be restorations that require excessive occlusal adjustments. This can be avoided by filling the entire set tray material where the teeth depressions are with syringeable material, to provide a uniform impression.

DUAL ARCH TRAYS

Dual arch trays work well for fixed prosthetic applications as long as the patient has holding contacts in the section of the arch to be restored. As indicated, it is important that at least one tooth mesial and distal to the prepared tooth be captured in the impression. Dual arch trays are available as posterior quadrant, anterior arch, $\frac{3}{4}$ arch and full arch versions. When the tray is inserted and the patient occludes, it is important that maximum intercuspation be observed on the adjacent side (Figure 12). When using

anterior dual arch trays it is often difficult to determine if the patient has occluded fully, so a separate bite should be provided to the laboratory in a very stiff PVS material designed for occlusal records. Posterior and $\frac{3}{4}$ quadrant trays have a distal loop on the tray to stabilize the tray at insertion. It is critical that the patient not occlude on this loop as this will lead to distortion of the tray and resulting spring back when the tray is removed.

Upon removal of the dual arch tray impression, the clinician should be able to see contacts through the material to the trays mesh where the teeth are intercuspated (Figure 13). Holding the tray up to the light should reveal illumination at these contact points. An impression that was improperly occluded will show lack of occlusal shine through and thicker material between the arches. If there is any chance that the laboratory cannot verify the occlusion, a separate bite should be taken with an appropriate PVS material and included with the case.

SURFACE CONTAMINATION

A less common problem, can present as unset impression material on the surface of the set tray material. This presents as an unset tacky layer (Figure 14). Exposure to air inhibited

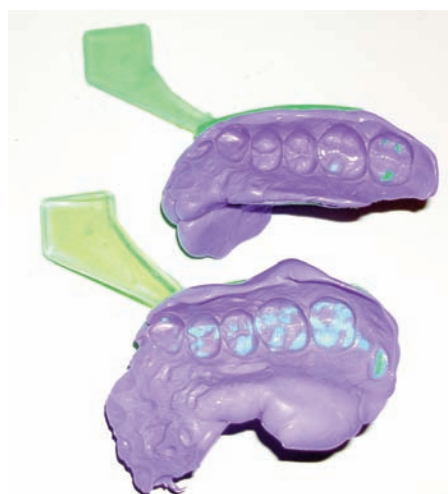

FIG 13: Proper intercuspation during impression. Note full intercuspation on the left side

methacrylates (e.g., composites, adhesives, core build-up materials, bis-acryl temporary crown and bridge materials) may leave a greasy coat on the prepared tooth that inhibits the material's ability to set correctly. When using two-step impressions, failure of the syringeable material to adhere to the tray material may occur when the preliminary impression is utilized to fabricate the temporary prosthesis. Wiping down both the tooth

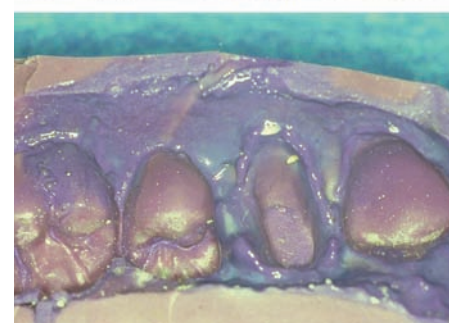



FIG 14: The polyvinylsiloxane material remained unset due to surface contamination

and preliminary impression with alcohol to remove the greasy air-inhibited layer can prevent these issues. The following may transfer sulfur to critical areas of the impression and cause inhibition of setting reaction of the



MEDESY

The art of quality



Medesy is glad to introduce **GAMMAFIX™**, a new range of sterilization trays. The quality and functionality of these trays facilitate the cleaning and sterilization process. Their special shape allows an extremely safe handling of the surgical instruments during the washing and sterilization phases. We selected the finest stainless steel to withstand the thermal shock caused by the constant sterilization cycles.







NEW GENERATION TRAYS



1670/1 DIAGNOSTIC SET

www.medesy.it



PRODUCT OF ITALY

prosthodontic section



FIG 15: Streaking of the impression material may occur due to inadequate mixing

marginal PVS material: retraction cords and solutions containing ferric sulfate or aluminum chloride; glove contact of the prepared teeth or surrounding tissues; rolling retraction cord in gloved fingers; or the use of a rubber dam. Rinsing the area with mouthwash or water after rubber dam removal and thoroughly drying can avoid this problem. Latex contamination of the putty can occur when mixing by hand. This may be avoided by washing the gloved hands to remove any residual powder and surface sulfides. Immersion of the impression in common disinfecting solutions (i.e. phenols and glutaraldehydes) used for periods of time up to 60 minutes has not shown clinically significant distortion of the impression material.^{10,11} Although, overnight immersion is not recommended as this may result in a decrease in accuracy of the final cast.¹²

INADEQUATE IMPRESSION MATERIAL MIXING

Once the impression material is combined, it should contain a uniform colour with no streaking. Streaking is more common with hand mixed putty materials than with cartridge materials (Figure 15). This may also occur if the automix cartridge is not bled prior to attaching the mixing syringe. When hand mixing putty, the material should be kneaded quickly to keep within the working time and yield a uniform color when completed.

CAST DISCREPANCIES

Large bubbles on the cast will correspond to a defect in the impression material (Figure 16). These bubbles are invariably caused by an insufficient amount of impression material or air trapped between the impression material and the arch at tray insertion. These defects can be avoided by syringing material around the teeth and into the

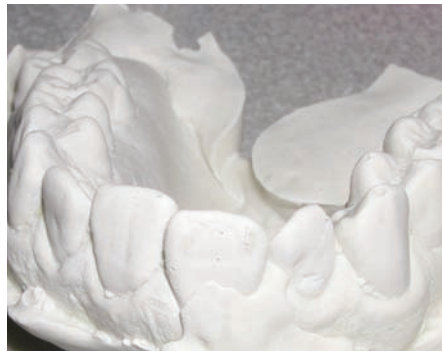

FIG 16: Appearance of a cast created using an impression that contained a void. Note the lack of definite detail



FIG 17: The cast is covered with multiple bubbles resulting from hydrogen gas release from the PVS material due to pouring of cast too early

vestibule prior to tray insertion. In patients with deep palates, it is also advisable to place some impression material into the depth of the palatal vault. Should the impression be removed and a void is noted due to air entrapment, a wash impression can be used to fill the void. It is advisable that the interproximal material is removed from the impression to allow full seating and the entire tray be covered in the syringeable material to ensure a continuous impression with no "step" appearance.

A cast that is covered with multiple tiny voids while the impression does not have corresponding defects can be the result of hydrogen gas release from the impression (Figure 17). Hydrogen is a by-product of PVS polymerization. Should the cast present with this defect, if the impression is still intact it can be re-poured. This defect can be avoided by following the manufacturer's recommendation with regard to the duration that should be observed prior to pouring the cast.

CONCLUSION

Complications during the impression

process can be perplexing to both the dentist and laboratory technician. Some of the more common concerns include tearing, voids, bubbles, and tray contact. This article addresses solutions for correction of some of the most prevalent impression defects that are experienced in clinical practice. By taking the necessary precautions to avoid damaged impressions, clinicians can ensure improved accuracy in communication of critical parameters as well as an overall improvement in restorative fit.

Acknowledgments: The authors mention their gratitude to Gary Hult, 3M ESPE, St. Paul, MN, Christopher Gross Dentsply Caulk, Milford, DE, Maribelle Velasco Kerr/Sybron Orange, CA, Dr. Mark Patel and Linda Bellisario, Heraeus Kulzer, Armonk, NY, and Mark Mumme, RDT, Falcon Dental Laboratories for providing the images that accompanied this article. The authors declare no financial interest in any of the products cited herein.

For a complete list of references, email info@dental-practice.biz

About the AUTHORS



Dr. Gregori Kurtzman is in private practice in Silver Spring, Maryland and an Assistant Clinical Professor, Department of Endodontics, Prosthetics & Operative Dentistry, University of Maryland, Baltimore School of Dental Surgery, Baltimore, Maryland.

Dr. Howard Strassler is a Professor and Director, Operative Dentistry, Department of Endodontics, Prosthetics & Operative Dentistry, University of Maryland, Baltimore School of Dental Surgery, Baltimore, Maryland.

Dr. Lanka Mahesh is an implantologist practicing in New Delhi. He is a Fellow and Diplomate of International College of Oral Implantologists (USA) and the Indian Society of Oral Implantologists. He has undergone advanced surgical training at USA and Spain. He has also authored "Practical Guide to Implant Dentistry" published by Quintessence. He has lectured extensively in India and abroad and has numerous publications on implant related topics.