

Advances In Dental Implant Impressions

Dr. Kurtzman is in private general practice in Silver Spring, Maryland. He has lectured both nationally and internationally and is privileged to be on the editorial board of numerous dental publications, a former Assistant Program Director for a University based implant maxi-course. He has earned Fellowship in the Pierre Fauchard Academy and Academy of Dentistry International (ADI). Dr. Kurtzman has been honored to be included in the "Top Leaders in Continuing Education" by Dentistry Today annually since 2006. He can be contacted at dr_kurtzman@maryland-implants.com.

Dr. Lanka Mahesh, BDS has done MBA and Diploma in Hospital Administration and Hospital Management. Dr.Lanka has also completed Masters Certificate in Implant Dentistry from UCLA, USA & CUFD, Thailand. Dr. Lanka Mahesh is Fellow and Diplomate of ICOI, USA. He is on the Editorial Board Of Journal Of Implants And Clinical Dentistry, Jiaacd- USA, and Journal Of The Academy Of Oral Implantology among many others.

Dr Lanka Mahesh is the Author of textbook Practical Guide To Implant Dentistry. Currently Dr.Lanka is in private specialised Implant practice at New Delhi. Apart from that he conducts various implant training programmes all over the country & he has trained more than 600 students in this field.



Dr. Lanka Mahesh



Dr. Kurtzman

Dental impressions form the back bone of the treatment we provide, whenever indirect restorations are planned. Yet, most practitioners don't place enough attention to the impressions they are taking. Dental laboratories consistently complain that the quality of impressions arriving in their lab tends to be of low quality, making their task more difficult in fabricating the desired restorations. The Samet study reported that 89% of impressions sent to labs have visible errors.¹

Impression quality is most critical with fixed prosthetics when implants are being restored. As implants do not have the periodontal ligament that natural teeth have, slight discrepancies between fixtures created in the impression prevent passive fit of the completed prosthesis. This lack of passive fit creates stresses on the implants which can lead to crestal bone loss as well as strains on the components leading to potential screw breakage or prosthetic failure.

Closed Tray vs Open Tray

Implant fixtures that will be restored with a prosthesis that is fixated to the fixtures with a screw can be captured using impression heads placed upon the fixtures. Unlike impressions of natural abutments with regard to implant impressions we do not have to use retraction methods to capture subgingival aspects of the implant fixtures. An impression head is placed upon the individual fixtures and is picked up in an impression either through a closed or open tray technique.

Differences do exist between the two techniques and there are reasons to favor one over the other clinically. Although the closed tray technique takes less clinical expertise than use of open tray impression heads, they do require reorientation of the impression head back into the impression upon removal intraorally. If not oriented correctly in the horizontal axis (placed into the impression rotated to its correct position) this can create problems with the implants connector. When working with non-splinted restorations, the resulting restorations will be rotated in relation to their desired position. If not inserted completely (vertical axis), the resulting restoration will not be

in the desired occlusal relationship. Additionally, as less rigid impression materials are often usually used in closed tray techniques to permit reinsertion of the impression abutment back into the impression discrepancies can be created between the individual fixtures.

Verification stents² to ensure accuracy between fixtures can not be utilized at the impression stage with closed tray impression abutments as the impression can not be removed without tearing it from the stent and abutments. Should a verification stent be desired to verify the master cast, this requires a separate appointment to try this in and may require alteration of the master cast by the laboratory prior to prosthesis fabrication. For this reason open tray impression heads offer clear benefits to the clinician and laboratory. They allow more rigid impression materials to be utilized ensuring that the fixtures are captured in relationship to each other in proper orientation. A verification stent can be fabricated at the time of impression eliminating a separate appointment to verify the master cast. Additionally, as the impression abutments are embedded within the impression when it is removed intraorally we also eliminate issues associated with reinsertion of the impression abutment back into the impression.

Traditionally, open tray impressions were fabricated either by creation of a custom tray with openings in the occlusal surface of the tray or through the use of a stock tray that was modified with openings in the occlusal surface. Should a custom tray be selected, additional time and cost is involved requiring a preliminary impression and model poured followed by fabrication of the tray in the lab.

The challenge with either of these approaches is that upon insertion of the tray filled with impression material one has to rotate the tray so that the long pins exit at the predetermined occlusal openings. This becomes more challenging with greater number of fixtures in the arch and when fixtures in the second molar region are present.

Miratray Implant Advanced Tray

The Miratray Implant Advanced Tray simplifies the process of taking open tray implant impressions. The tray is provided in three maxillary and three mandibular sized trays and the trays are unique in their design. (Fig. 1) The occlusal surface is covered by a transparent foil. This allows identification of the heads of the pins easily intraorally. Retention slots and an internal rim

provide mechanical retention to retain the impression material within the tray. Should the practitioner choose to supplement the retention with a PVS adhesive, it is recommended that it not be applied to the foil surface as this may obscure visualization of the pins when inserting the tray to proper depth. Additionally, it should be noted that PVS adhesive does not adhere to putty PVS materials and do not therefore increase retention of the impression material to the interior of the tray. The PVS adhesive does adhere to all other PVS viscosities.



Fig 1. Maxillary and mandibular Miratrays available in small, medium and large sizes.

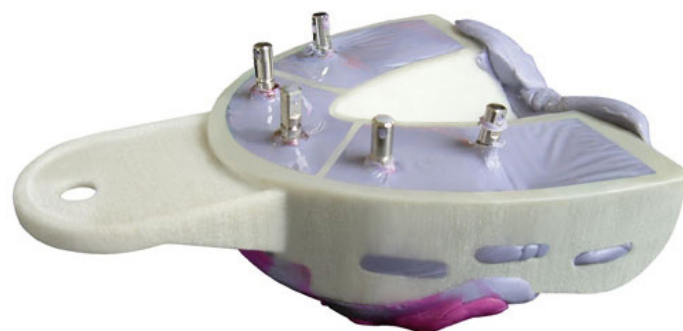

Fig 2. A maxillary full arch impression of 5 implants taken with a Miratray upon removal intraorally.

The technique involves filling the tray with an appropriate impression material, the author recommends either a universal body PVS or a tray or putty PVS. The tray is then inserted over the open tray impression heads intraorally and pressed down crestally until the top of the impression pins are visible through the transparent foil. The practitioner then presses the tray further until the pins puncture the foil and are visible protruding through the foil. This contains the impression material within the tray without the potential problem often seen with use of custom or modified stock trays of the impression material obscuring the tops of the pins. Upon setting, the pins are rotated in a counterclockwise fashion and removed from the impression and the impression is removed intraorally. (Fig. 2) Due to the design of

the tray, it can be used in all implant impression situations whether the arch is partially dentate or fully edentulous.

Case example

Patient presented ready for prosthetic phase of a single implant in the maxillary 2nd premolar and an adjacent crown on a natural molar. The treatment plan would restore the implant at the second molar with a custom abutment and restore the site with a cemented bridge with a cantilever pontic at the 1st premolar. Following preparation of the molar, an open tray impression abutment was placed on the implant fixture. (Fig. 3) The Miratray was tried in to verify that it was large enough to capture all of the teeth in the arch without impingement on teeth or soft tissue. (Fig. 4). A polyvinyl siloxane impression material was injected around the gingival aspect of the open tray impression abutment and the sulcus of the molar preparation. The Miratray was filled with additional impression material and inserted intraorally. As the tray was pressed gingivally, the long pin was allowed to perforate the clear foil on the occlusal aspect of the Miratray. (Fig. 5). Upon setting, the long pin was removed and the Miratray impression removed intraorally and was sent to the laboratory for prosthetic

fabrication. (Fig. 6 & 7). A master cast was created from the impression and the prosthetics were completed and returned for insertion. (Fig. 8)

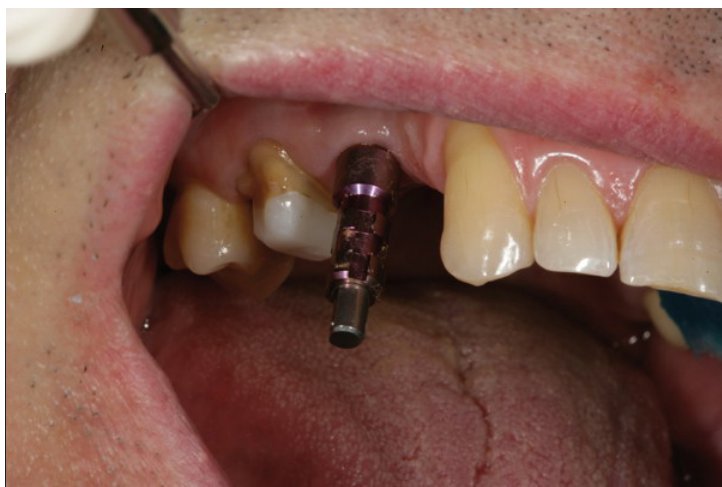

Fig 3. Open tray impression abutment placed upon an implant in the 2nd premolar.

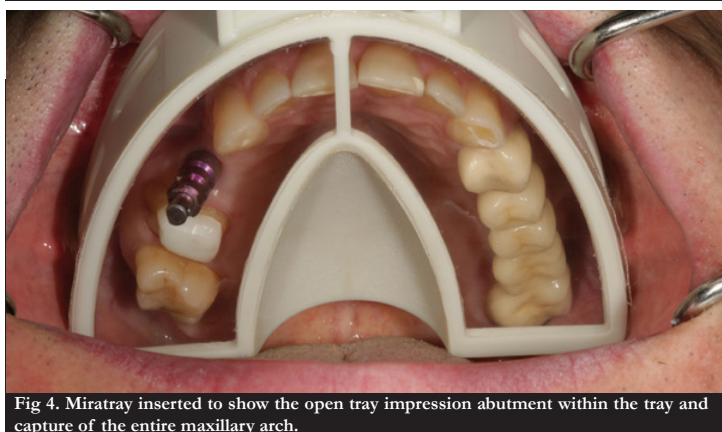


Fig 4. Miratray inserted to show the open tray impression abutment within the tray and capture of the entire maxillary arch.

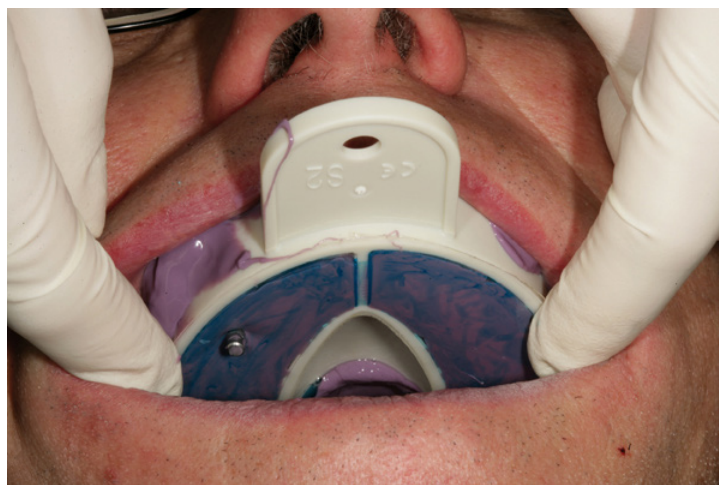

Fig 5. Miratray filled with impression material inserted intraorally and long pin exiting the clear foil of the tray

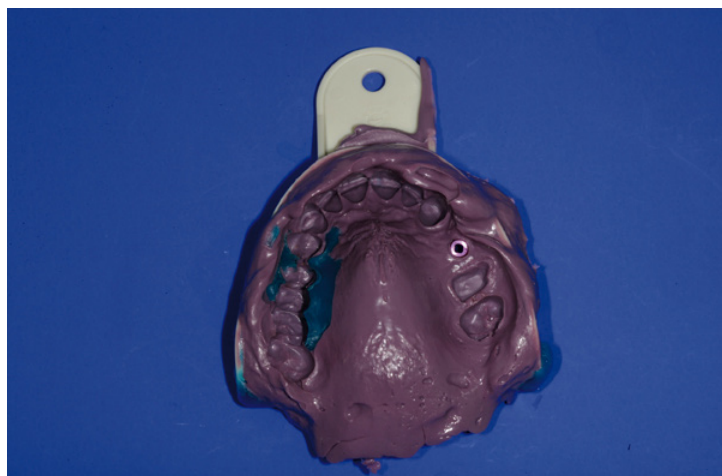


Fig 6. Impression upon removal intraorally showing the embedded open tray impression abutment.



Fig 7. Exterior of the Miratray impression showing the long pin removed from the clear foil after removal intraorally.

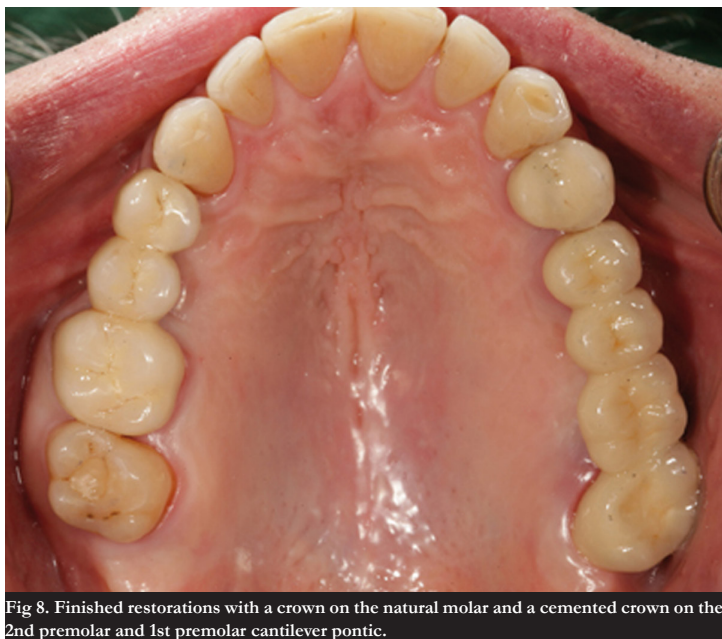

Fig 8. Finished restorations with a crown on the natural molar and a cemented crown on the 2nd premolar and 1st premolar cantilever pontic.

Conclusion

Impressions can be a challenging aspect of implant dentistry. Good impressions are the key to providing great dental restorations and inaccuracies at the beginning of the process multiply in their effects on the result as the process progresses. For this reason practitioners need to capture the most accurate impressions at the start of the process that will be concluded at the laboratory. Selection of proper trays and impression techniques can improve the resulting impressions.

Reference:

1. Samet N, Sbofat M, Livny A, Weiss EI. A clinical evaluation of fixed partial denture impressions. *J Prosthet Dent* 2005; 94:112-117.
2. Silverstein LH, Kurtzman GM, et al.: The utilization of a preprosthetic extraoral verification stent for dental implant-supported reconstructions. *Dent Today*. 2002 Jan;21(1):88-91.
3. Kwon JH, Son YH, Han CH, Kim S.: Accuracy of implant impressions without impression copings: a three-dimensional analysis. *J Prosthet Dent*. 2011 Jun;105(6):367-73.

For Mixed Infections

Cefiwok[®] OZ
Cefixime 200 mg + Ornidazole 500 mg Tablets

XTRA COVERAGE For MIXED INFECTIONS

Better Dissolution:
Micronized form of both Cefixime (200 microns) & Ornidazole (200 microns)*

Faster Release of Drug:
In built super disintegrant*

Manufactured in WHO-GMP certified plant*

*Data on File