

Histologic and Clinical Evaluation of a Bioactive Calcium-Phosphosilicate Bone Graft Material in Post-Extraction Alveolar Sockets

Aron Gonshor, PhD, DDS¹ • Lanka Mahesh, BDS, MBA, MS²
Stephen A. Saroff, DDS, MSD³ • Frederic P.C. Joachim, DDS, MSc⁴
Jacques A. Charon, DDS, MSc⁵

Abstract

Background: Long-term success of dental implants has been demonstrated when placed simultaneously with or after a socket grafting procedure. Although optimal bone formation can be from 6 to 9 months or longer with grafting materials other than autogenous bone, utilization of bone allograft eliminates patient morbidity through elimination of autograft harvest sites.

Methods: This study evaluated bone formation following grafting of 22 post-extraction alveolar sockets with bioactive calcium phosphosilicate putty (CPS Putty) graft material.

Results: At 5-6 months post grafting there was bone regeneration showing both normal clinical attributes and radiographic trabecular appearance. Histomorphometric analysis revealed average vital bone content of 48.2% \pm 6.8 to residual graft content of 2.4% \pm 1.4 for the 22 sockets in the study, at an average healing period of 5.4 months \pm 1.5.

Conclusions: The high percentage of vital bone content, after a relatively short healing phase, suggests that CPS Putty can be a reliable choice for osseous regeneration in cases of crest preservation and implant related surgeries.

KEY WORDS: Site preservation, bone graft, allograft, extraction, dental implants

1. Lecturer, Faculty of Dentistry, McGill University, Montreal, Quebec, Canada.

2. Private Practice, New Delhi, India.

3. Periodontal Private Practice, Richmond, Virginia, USA.

4. Periodontal Private Practice, Lille, France.

5. Periodontal Private Practice, Lille, France.

INTRODUCTION

Extractions occur primarily as a result of periodontal disease, caries or trauma. Caries is endemic and a leading cause of tooth loss in the US population. Periodontal disease is responsible for 30-35% of extractions in people over 40 years of age.¹ Clinically it is important to replace missing teeth with the most suitable option for the patient, so that ridge and site preservation at the time of extraction is critical to long term success, irrespective of the procedure used for tooth replacement.²

Autogenous bone has been considered the "gold standard" for filling bony defects, especially large defects resulting from cysts and tumors, alveolar resorption, and periodontal bony defects, all of which leave insufficient bone for the placement of implants. The cancellous portion is usually used and it is rich in mesenchymal cells, which are generally involved in osteogenesis. However, clinical situations, such as the size of the bony defect, absence of enough donor tissue, or the need for a second intervention, may preclude its use.

The ongoing development of biomaterials has improved the characteristics and properties of potential synthetic bony substitutes.³ The challenge has been to assess the interface between the biomaterial and the host.⁴ Alloplastic bioactive graft substitutes are a potential advance in solving this issue. A bioactive material is defined as one that will create a biological response that will prevent a fibrous repair at the interface, but rather lead to a bony union of the material and the host tissue.⁵ Bioactive glass ceramics have demonstrated such biocompatibility and direct contact with bone.⁶ The first bioactive material was reported in 1971.⁷ It was a four-component oxide mixture, consisting of 45% silica dioxide, 24.5% sodium, 24.5% calcium and 6% phos-

phorous. This product has evolved and is now being marketed as a pre-mixed, moldable material called NovaBone Dental Putty® (US Biomaterials Corp., Alachua, Fla.) consisting of four components: two bioactive phase components - a 55% standard calcium phosphosilicate (CPS) particulate, and a 14% CPS smaller particulate - as well as a 12% polyethylene glycol additive phase and a 19% glycerin binder phase. In dentistry this latter putty form of calcium phosphosilicate is designed for osseous regeneration of periodontal bone defects, filling of alveolar sockets, sinuses and augmentation of alveolar ridges.

The purpose of this study was to clinically, radiographically and histologically evaluate CPS Putty when used as a bone graft material in human alveolar post-extraction sockets.

MATERIALS AND METHODS

Material

Bioactivity is initiated immediately upon implantation. The smaller CPS particles release calcium and phosphorous ions into the area, the binder material gets absorbed over a period of a week exposing the larger CPS particulates to blood. Breaking the silicon-oxygen bonds releases silicic acid, which forms a negatively charged gel at the particle surface. In several hours calcium phosphate is produced in the gel, which then crystallizes into a new surface apatite layer. Bioactivity begins in this surface layer when collagen, glycoproteins and mucopolysaccharides from the surrounding bone are incorporated into the apatite layer. This helps to produce a direct chemical bond with the host bone. In vivo, the graft substitute bonds to connective tissues and to bone.⁸ The apatite layer helps in the stimulation of osteoprogeni-

tor cells to produce transforming growth factor, by the release of silicon from the surface.^{3,9-12}

Methods

There were 22 patients (14 males and 8 females), between the ages of 25 and 79 (mean of 51), requiring tooth extraction. The surgical procedures were performed only in private offices. Patients were screened, and all provided written and oral consent. They were enrolled from October 2008 to August 2010, and the study was conducted in accordance with the Helsinki Declaration of 1975, as revised in 2000. The case-selection criteria included the absence of acute periodontal or odontogenic disease; women who were not pregnant nor intended to become pregnant during the study period; no history of cancer or human immunodeficiency virus; no untreated periodontal disease, including periapical disease; and the absence of any medical condition or therapeutic regimen that alters soft and/or hard tissue healing (i.e., osteoporosis, hyperparathyroidism, autoimmune diseases, chemotherapeutic or immunosuppressive agents, steroids, bisphosphonates, or similar type drugs).

All cases in this study were tooth extractions with immediate socket grafting. The teeth chosen for removal had little if any periodontal involvement. They were for the most part fractured teeth. Care was taken to remove the teeth atraumatically, so as to preserve the surrounding bone. In all cases the sockets had 4 or 5 wall defects. Any socket with a significant bone dehiscence was excluded from the study. After extraction the sockets were debrided and any inflammatory granulation tissue removed, also ensuring that there was suitable residual bleeding. The sockets were then filled with the CPS Putty material (Figures 1a, 1b),

being careful not to touch the material with surgical gloves, or to impact the material too tightly. The volume of putty material used varied from 0.5cc to 1.0cc. No membranes were placed. Mucosal and periosteal releasing incisions were created to allow for tension-free primary closure, using 3-0 or 4-0 plain gut or chromic sutures. No pre or post-operative antibiotics were administered, and all patients were placed on Chlorhexidine oral rinse post-operatively. Pre and immediate post-operative radiographs were taken. Patients were then followed clinically and radiographically at time intervals of 1 week, 2-3 weeks, 6-8 weeks and 3-4 months. At the latter visit there was a discussion as to subsequent implant placement, which took place within the 3-6 month period. A number of patients decided against implant therapy.

Core Biopsies

In this study, on the day appointed for implant surgery, prior to the implant placement, a trephine bur with a 2.7-mm internal diameter (3.5 mm external diameter) was used to obtain a bone core from the center of the regenerated socket. The cores were left within the trephine and placed in 10% neutral buffered formalin for fixation. Decalcified specimens were prepared in 14 of the 22 cases that opted for subsequent implant placement. Undecalcified preparations were performed in the remainder (8 cases), with subsequent histomorphometric analysis.

Histologic Preparation

Undecalcified histologies were performed by the Division of Anatomic Pathology, University of Connecticut, Framington, Connecticut, USA. Specimens were fixed in formalin prior to decalcification. A stronger decalcification solution was

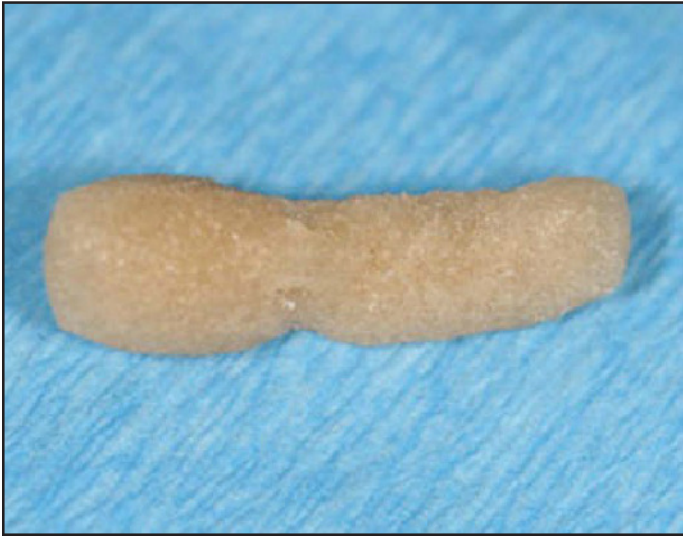

Figure 1a: Calcium phosphosilicate bioactive bone in moldable putty form.

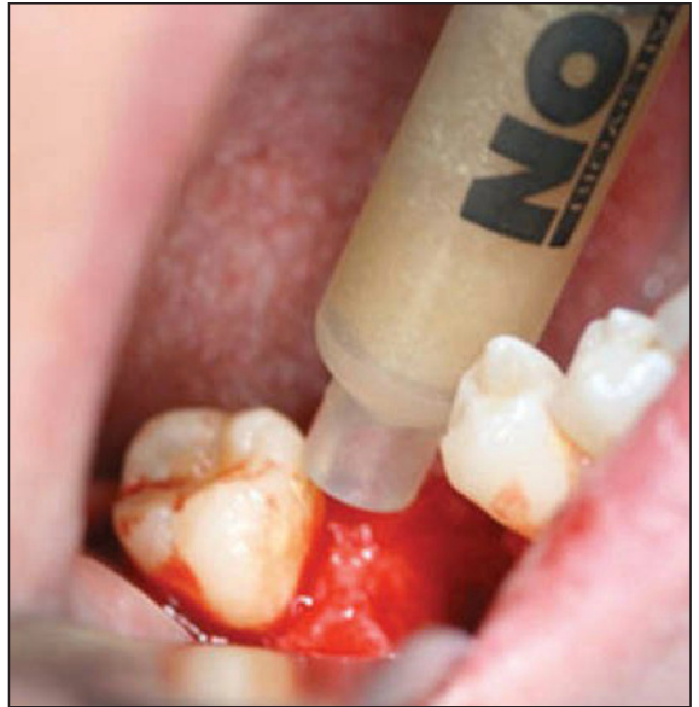


Figure 1b: Calcium phosphosilicate bioactive bone in syringe injectable paste.

used for dense bone cores (eg. Mandible). A high speed bone decalcifier-Decal Stat, [hydrochloric acid], (Decal Chemical Corp.) was used for decalcification of samples. The slides were stained with modified Hemotoxylin/Eosin and histologic analysis was performed. All histologic preparations for histomorphometrics were performed by the Division of Pathology, University of Minnesota, Minneapolis, Minnesota, USA. Upon receipt, specimens were dehydrated with a graded series of alcohols for 9 days. Following dehydration, the specimens were infiltrated with a light-curing embedding resin (Technovit 7200 VLC, Kulzer, Wehrheim, Germany). Following 20 days of infiltration with constant shaking at normal atmospheric pressure, the specimens were embedded and polymerized by 450 nm light; the temperature of the specimens

never exceeded 40°C, then cut and ground.^{13,14} Specimens were prepared in an apico-coronal direction (parallel to the long axis) and were cut to a thickness of 150 μm on a cutting/grinding system (EXAKT Technologies, Oklahoma City, OK, USA). The cores were polished to a thickness of 45-65 μm with a series of polishing sandpaper disks from 800 to 2,400 grit, using a microgrinding system, followed by a final polish with 0.3 μm alumina polishing paste. The slides were stained with Stevenel's blue and Van Gieson's picro fuchsin and coverslipped for histologic analysis using brightfield and polarized microscopy.

Histomorphometry

Following non-decalcified histologic preparation, the cores were evaluated histomorpho-

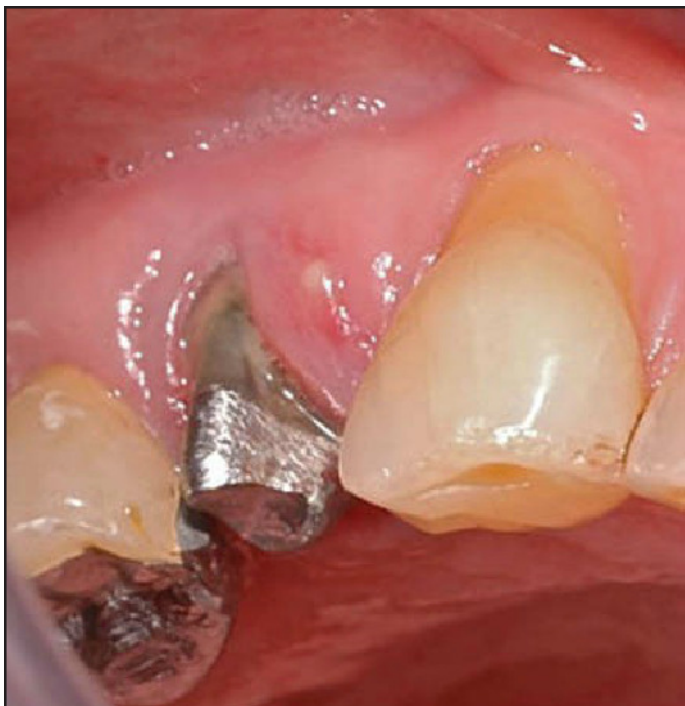

Figure 2A: Pre-surgical view of maxillary right first premolar with buccal fistula.

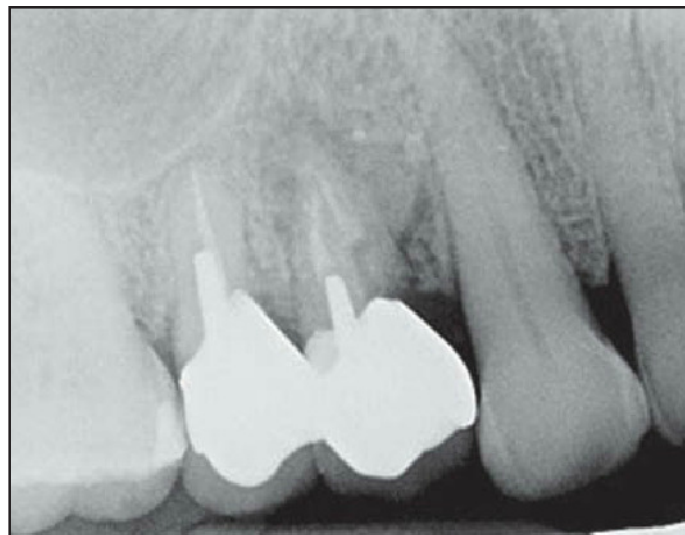

Figure 2B: Pre-surgical radiograph of maxillary right first premolar demonstrating periapical lesion and root fracture.

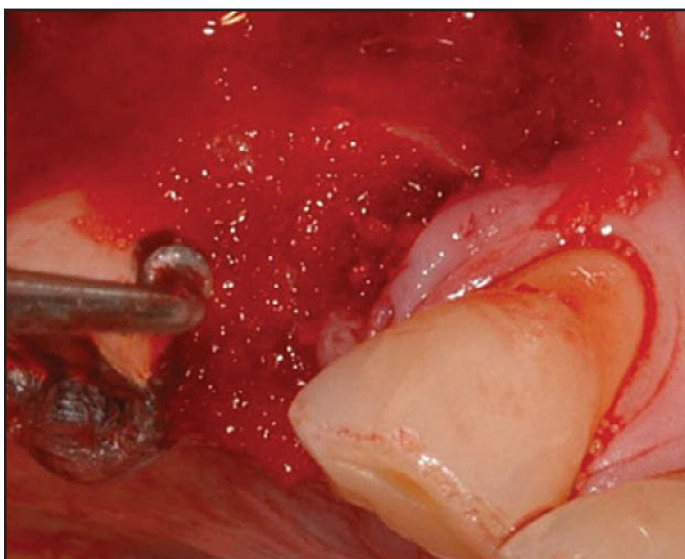


Figure 3: Placement of CPS Putty into #5 alveolus. Note the loss of buccal plate.

metrically. The cores were digitized at the same magnification using a microscope (Zeiss Axiolab, Carl Zeiss MicroImaging, Thornwood, NY, USA) and a digital camera (Nikon Coolpix 4500, Nikon, Melville, NY, USA). Histomorphometric measurements were completed using a combination of programs (Adobe Photoshop, Adobe Systems, San Jose, CA, USA; NIH Image, National Institutes of Health, Bethesda, MD, USA). Parameters evaluated were the total area of the core, percentage of new bone formation, and percentage of residual graft material. The remainder of the area was considered soft tissue or void. The primary slide evaluated for each specimen was from the most central region of the obtained core. No comparison was made between the apical and coronal sections.

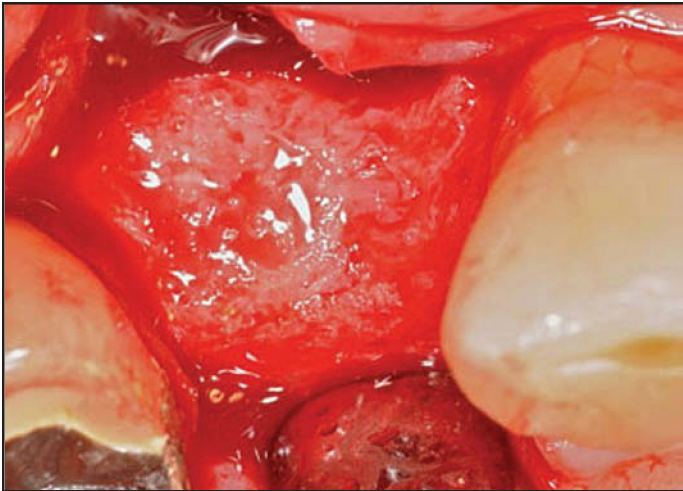


Figure 4A: Occlusal view of regenerated alveolar crest with CPS Putty replaced by new bone, including the area of buccal bone loss.

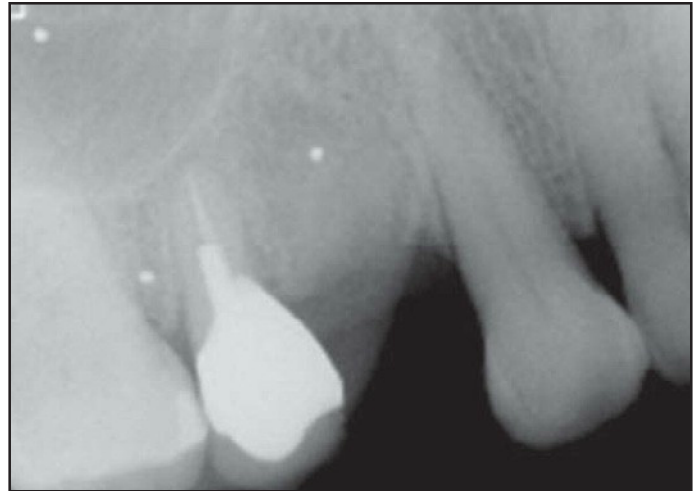


Figure 4B: Normal trabecular appearance of the regenerated alveolus.

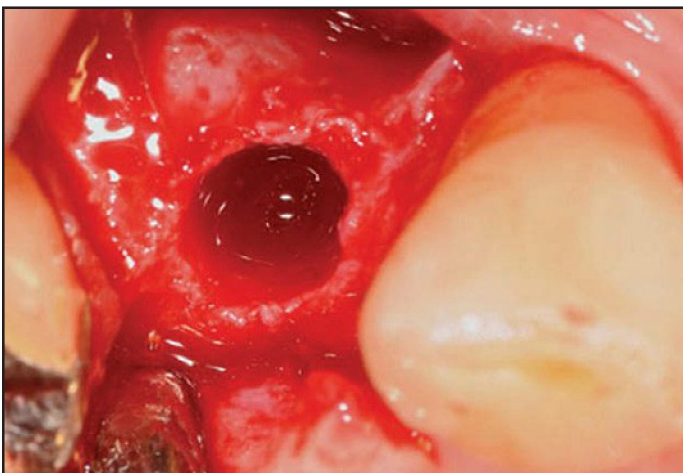


Figure 5: Occlusal view of implant osteotomy, showing robust vascularity.

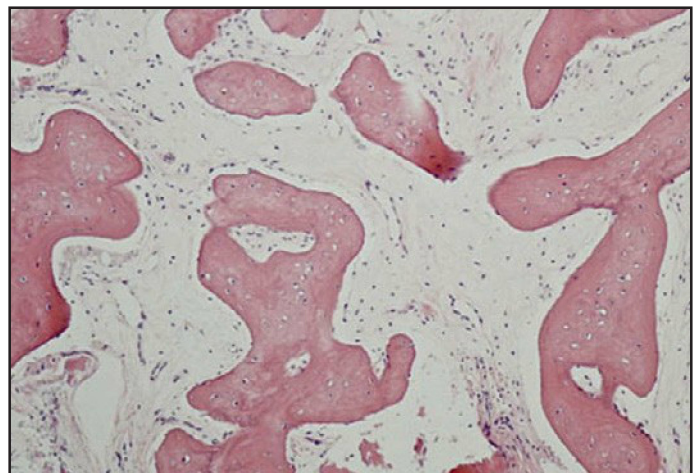


Figure 6: High magnification histological view

RESULTS

The study consisted of 22 alveolar sockets in all. 17 sockets were in the maxilla, with 11 in the anterior, cuspid-to-cuspid region and 6 in the posterior, premolar-molar region. In the mandible the remaining 5 sockets were in the molar region only. At the 5-6 month (average

5.4) post graft period all sockets demonstrated dense bone fill, with no visual evidence of residual graft material. Clinically, there was no significant difference noted in the “tactile feel” when drilling into treated sites as compared to adjacent non-treated sites, with bleeding in the graft site osteotomies showing clear evidence of vas-

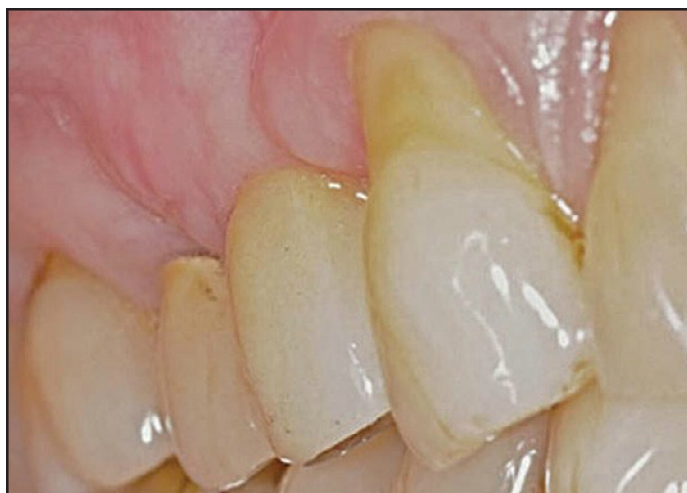

Figure 7: New crown on tooth #5, showing the elimination of the pre-treatment gingival recession.

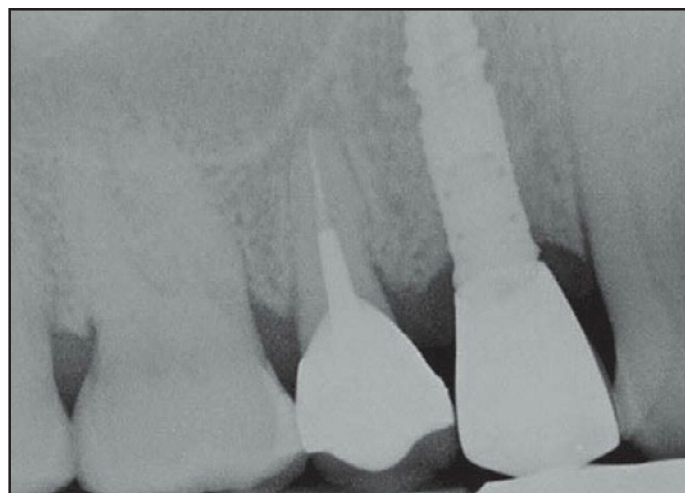


Figure 8: Radiograph of the implant #5. Note normal bone trabeculation pattern.

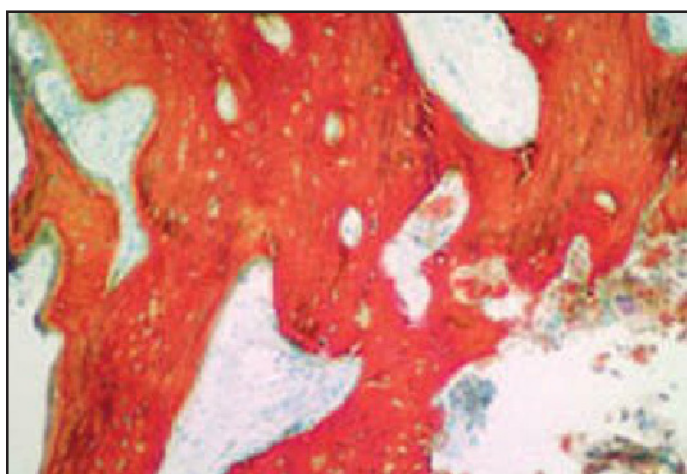


Figure 9a: Undecalcified cores at 5.5 months (100x magnification). Red-stained tissue is mineralized, newly regenerated bone with visible cell nuclei. Residual graft material can be seen.

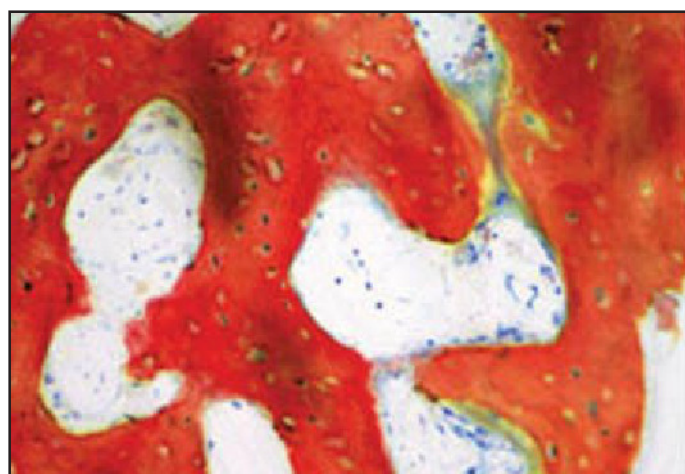


Figure 9b: Undecalcified cores at 5.5 months (200x magnification). Red-stained tissue is mineralized, newly regenerated bone with visible cell nuclei. Residual graft material can be seen.

cular ingrowth. Radiographs demonstrated very substantial bone fill in the sockets. The trabecular pattern in the regenerated areas appeared very similar to the adjacent (native) bone.

A representative case is that of a 74 year old female, in stable health, who presented with a

fistula in the buccal mucosa of the upper right first premolar (Figure 2a). Radiographic evaluation revealed a periapical lesion, secondary to a root fracture (Figure 2b). After evaluation, the decision was made to extract the tooth, with the view to eventual implant placement. The

tooth was extracted atraumatically, at which time it was determined that the quality of bone was insufficient for immediate implant placement, due to a significant loss of buccal plate. The alveolus was curetted and CPS Putty was placed (Figure 3). The patient was recalled 4 months post graft for evaluation, and a decision was made to place an implant at that time. After raising a full thickness flap at the crest of the ridge it was noted that the CPS Putty had been replaced by regenerated bone that had a normal clinical and radiographic appearance (Figures 4a, 4b). The quality of the regenerated bone was excellent with healthy natural bleeding and a completely regenerated buccal plate, which permitted normal implant placement (Figure 5). A core was taken prior to implant placement. A representative high magnification sample of the decalcified Hematoxylin-Eosin sections shows substantial portions of vascularized dense vital bone, interspersed with a normal connective tissue matrix (Figure 6). The final prosthetic result showed a normal clinical crown form with healthy peri-implant tissue (Figure 7), as well as a normal trabecular bone appearance (Figure 8).

Figures 9a and 9b shows representative histologic images of an undecalcified core, at increasing magnifications, taken from the bone graft site of a separate case. Histomorphometric evaluation of all the undecalcified cores revealed an average vital bone content of $48.2\% \pm 6.8$ (standard deviation). As a comparison, autogenous trabecular bone volumes, which can vary widely, have a range from under 20% to 40%.¹⁵ A residual graft content of $2.4\% \pm 1.4$ was found for the calcium-phosphosilicate bone graft, following a healing time of 5.4 months \pm 1.5 months.

DISCUSSION

The results of the present study show that in post-extraction alveolar sockets, CPS Putty graft material is able to achieve bone regeneration results that are favorable for the placement of subsequent osseointegrated implants. In addition, by eliminating the need for second site donor harvesting and the resulting increased risk of morbidity, the use of this synthetic graft substitute becomes very appealing.

Historically the function of biomaterials has been to replace damaged and missing tissues.^{7,16} Compositions such as 45S5 Bioglass, having the highest bioactivity rate, allow for rapid trabecular bone regeneration with an architecture, volume and bio-mechanical bone quality that matches the original bone in that region.¹⁷ The multi-stage mechanisms and kinetics of surface reactions of CPS and bone have been extensively covered.^{18,19} What is clear is that the surface reactions take place within a short, 2-4 day time frame,²⁰ with attachment of stem cells and the subsequent proliferation and differentiation of osteoblasts rapidly occurring on the surface of the bioactive material.^{21,22} Moreover, Xynos et al were able to show that modulation of the osteoblast cell cycle is achieved by the controlled release of ionic dissolution products from CPS particles.²¹ In particular, the ionic dissolution products of biologically active Silicon and Calcium released from these bioactive glasses stimulate the genes that control osteoblast differentiation, as well as proliferation. Gene array analyses confirmed that after several hours of exposure of human primary osteoblasts to the soluble chemical extracts from CPS particles, several gene families were up-regulated or

activated: Genes that encode for nuclear transcription factors and growth factors, especially IGF-II.²¹ Among the differentially expressed genes were those involve with cell cycle regulation, differentiation and proliferation, as well cell adhesion and bone mineralization.^{20,23,24} These studies all point to a capability possessed by CPS particles to stimulate differentiation toward a cell lineage with therapeutic potential in tissue engineering. In addition there is evidence that these particles possess a transient antimicrobial activity,²⁵ most probably due to a direct and indirect pH-related effect.²⁶

Human clinical studies and reports of bioactive glasses use have dealt, for the most part, with repair of periodontal and alveolar ridge defects, with more limited studies in orthopedics and other areas of the head and neck.^{10,11,27-31} Lovelace et al.³² showed that freeze-dried bone allograft gave similar pocket depth reduction in moderate and deep periodontal osseous defects when compared with CPS particles. Other authors who have treated infra-bony defects with CPS particles have shown similar results, with attachment gains of 2.7 to 3.0 mm and 2.8 mm and reductions in pocket probing depth of 3.7 to 4.4 mm,^{33,34} with preoperative probing depth at 7.9 to 8.1 mm. Significant improvement in probing depths has also been reported when CPS particles were used in the treatment of class II furcation defects.³ These results have not been uniform. Other authors have found only a slight, non statistically significant, improvement in infra-bony defects treated with CPS particles in comparison with those of controls treated with open debridement only.^{35,36} The reasons for the discrepancies between similar trials in the literature remain speculative but may

be attributed to various factors, including the disease and patient population variations, the types and depths of the defects, the baseline clinical conditions, or the evaluation methods used.³⁷ CPS particles have been used in a limited number of sinus augmentation studies. In a histomorphometric study comparing augmentation with 100% autogenous iliac crest bone to a composite graft, consisting of 80-90% CPS particles and 10-20% autogenous iliac bone, it was found that the composite graft accelerated healing time to about 6 months, compared to 12 months for the autogenous graft alone.³⁸ In a recent comparative histomorphometric study by Galindo-Moreno et al.³⁹ bone core biopsies were taken 6 months after sinus grafting with either a bovine hydroxylapatite (HA) or CPS particles. No bone loss was observed radiographically or clinically in both groups. Histologic analysis revealed that both grafts had a high biocompatibility. In the bovine HA-containing group, minimal xenogenic graft absorption was noted. In contrast, the CPS group samples presented a high absorption rate with some remaining particles imbedded in new normal bone.

In the present study tissue regeneration after graft placement occurred without complications. Most significantly, there was a very high level of bone formation within the implanted material. This was evidenced by new bone formation, including mature trabecular bone with osteocytes in lacuna, as well as marrow formation within the new bone structure. The degree of trabecular bone formation between the implant particles was consistent with the previously reported histologic results in animal models after a similar time frame.^{30,40} In these studies new bone formed around all particles,

ADVERTISE
ADVERTISE WITH
J I A C D
TODAY!

Reach more customers
with the dental
profession's first
truly interactive
paperless journal!

Using revolutionary online technology,
JIACD provides its readers with an
experience that is simply not available
with traditional hard copy paper journals.



WWW.JIACD.COM

with a progressive thickening of the bone layer as the particles decreased in size. The histologic findings of this study indicate that the graft material followed the same pattern of bone formation as seen in other human and animal studies. A high degree of neovascularization was seen within the grafted area, which is crucial for the support of new bone formation. There was no evidence of reduction of the overall size of the graft material and newly formed bone, although longer study duration would be necessary to demonstrate no long-term resorption. In addition there was no evidence, either clinically or histologically, of any significant inflammatory reaction surrounding the graft material, suggesting good tissue compatibility.

CONCLUSION

The high percentage of vital bone content, after a relatively short healing phase, suggests that bioactive calcium phosphosilicate putty can be a reliable choice for osseous regeneration in cases of crest preservation and implant related surgeries. ●

Correspondence:

Dr Aron Gonshor, 4980 Glencairn Avenue,
Montreal, Quebec, Canada, H3W 2B2.

FAX: 514 486 7010

Email: arongonshor@gmail.com

ACKNOWLEDGMENTS

NovaBone Products (Manufacturer of the bone graft material used in this study) provided partial research support for this project. The authors gratefully acknowledge the assistance of Dr. Michael Rohrer, director, Hard Tissue Research Laboratory and Oral Pathology Laboratories, University of Minnesota School of Dentistry, for the preparation of the specimens, the histologic data used for histomorphometric analysis, and the assistance of Dr. Easwar Natarajan at the University of Connecticut Health Center, Oral Pathology Diagnostic Service, Farmington, CT, for the preparation of the decalcified specimens.

DISCLOSURE

NovaBone Products (Manufacturer of the bone graft material used in this study) provided partial research support for this project.

REFERENCES

- Klinge B, Hultin M, Berglund T. Peri-implantitis. *Dental Clin North Am* 2005;49:661-676.
- Lekovic V, Kenney E, Weinlaender M, Han T, Klokkeveld P, Nedic M. A bone regeneration approach to alveolar ridge maintenance following tooth extraction: Report of 10 cases. *J Periodontol* 1997;68:563-570.
- Anderegg CR, Alexander DC, Freidman M. A bioactive glass particulate in the treatment of molar furcation invasions. *J Periodontol* 1999;70:384-387.
- Hench LL, West JK. Biological applications of bioactive glasses. *Life Chem Rep* 1996;13:187-241.
- Hench LL. Bioactive Ceramics. In *Bioceramics: Material characteristics versus in vivo behavior*, Ducheyne P, Lemons J, eds. *Annals N.Y. Acad Sci* 1988; 523: 54.
- Gross U, Strunz V. The interface of various glasses and glass ceramics with a bony implantation bed. *J Biomed Mater Res* 1985;19:251-271.
- Hench LL, Splinter RJ, Allen WC, Greenlee TK. Bonding mechanisms at the interface of ceramic prosthetic materials. *J Biomed Mater Res* 1971;5:117-141.
- Zhong JP, LaTorre GP, Hench LL. The kinetics of bioactive ceramics: part VII. Binding of collagen to hydroxyapatite and bioactive glass. In *Proceedings of the 7th International Symposium on Ceramics in Medicine: Bioceramics*, Anderson O.H. and Yli-Urpo, eds: Oxford: Butterworth-Heinemann, 1994.
- Price N, Bendall S, Frondoza C, Jinnah R, DS H. Human osteoblast-like cells (MG63) proliferate on a bioactive glass surface. *J Biomed Mater Res* 1997;37:394-400.
- Wilson J, Low SB. Bioactive ceramics for periodontal treatment: comparative studies in the Patus monkey. *J Appl Biomaterials* 1992;3:123-129.
- Cancian DC, Hochuli-Vieira E, Marcantonio RA, Garcia JIR. Utilization of autogenous bone, bioactive glasses, and calcium phosphate cement in surgical mandibular bone defects in *Cebus apella* monkeys. *Int J Oral Maxillofac Implants* 2004;19:73-79.
- Wilson J, Pigott GH, Schoen FJ, Hench LL. Toxicology and biocompatibility of bioglasses. *J Biomed Mater Res* 1981;15:805-817.
- Donath K, Breuner G. A method for the study of undecalcified bones and teeth with attached soft tissues. *J Oral Pathol* 1982;11:318-326.
- Rohrer MD, Schubert CC. The cutting-grinding technique for histologic preparation of undecalcified bone and bone-anchored implants:: Improvements in instrumentation and procedures. *Oral Surg Oral Med Oral Path* 1992;74:73-78.
- Watzek G, Ulm C, Haas R. Anatomic and Physiologic Fundamentals of Sinus Floor Augmentation. In: *The Sinus Bone Graft*. Jensen O, ed. Chicago: Quintessence, 1992:35-37.
- Hench LL, Polak JM, Xynos ID, Buttery LDK. Bioactive materials to control cell cycle. *Mat Res Innov* 2000;3:313-323.
- Hench LL, Polak JM. Third-generation biomedical materials. *Science* 2002;295:1014-1017.
- Ogino M, Ohuchi F, Hench LL. Compositional dependence of the formation of calcium phosphate films on bioglass. *J Biomed Mater Res* 1980;14:55-64.
- Oonishi H, Hench LL, Wilson J, Sugihara F, Tsuji E, Matsuura M, et al. Quantitative comparison of bone growth behavior in granules of Bioglass/E, AW glass-ceramic, and hydroxyapatite. *J Biomed Mater Res Part A* 2000;51:37-46.
- Hench LL, Polak JM. A Genetic Basis for Design of Biomaterials for In Situ Tissue Regeneration. *Key Eng Mater* 2008;377:151-166.
- Xynos ID, Edgar AJ, Buttery LDK, Hench LL, Polak JM. Gene-expression profiling of human osteoblasts following treatment with the ionic products of Bioglass/E 45S5 dissolution. *J Biomed Mater Res Part A* 2001;55:151-157.
- OrÉfice R, Hench L, Brennan A. Evaluation of the interactions between collagen and the surface of a bioactive glass during in vitro test. *J Biomed Mater Res Part A* 2009;90:114-120.
- Bombonato Prado KF, Bellesini LS, Junta CM, Marques MM, Passos GA, Rosa AL. Microarray based gene expression analysis of human osteoblasts in response to different biomaterials. *J Biomed Mater Res Part A* 2009;88:401-408.
- Carinci F, Palmieri A, Martinelli M, Perrotti V, Piattelli A, Brunelli G, et al. Genetic portrait of osteoblast-like cells cultured on PerioGlas. *J Oral Implantol* 2007;33:327-333.
- Waltimo T, Brunner TJ, Vollenweider M, Stark WJ, Zehnder M. Antimicrobial effect of nanometric bioactive glass 45S5. *J Dent Res* 2007;86:754-757.
- Gubler M, Brunner TJ, Zehnder M, Waltimo T, Sener B, Stark WJ. Do bioactive glasses convey a disinfecting mechanism beyond a mere increase in pH? *Int Endod J* 2008;41:670-678.
- Amato MM, Blaydon SM, Scribbick Jr FW, Belden CJ, Shore JW, Neuhaus RW, et al. Use of bioglass for orbital volume augmentation in enophthalmos: a rabbit model (oryctolagus cuniculus). *Ophthal Plast Reconstr Surg* 2003;19:455-465.
- Conejero JA, Lee JA, Ascherman JA. Cranial defect reconstruction in an experimental model using different mixtures of bioglass and autologous bone. *J Craniofac Surg* 2007;18:1290-1295.
- TeÚfilo JM, Brentegani LG, Lamano-Carvalho TL. Bone healing in osteoporotic female rats following intra-alveolar grafting of bioactive glass. *Arch Oral Biol* 2004;49:755-762.
- Leatherman BD, Dornhoffer JL. Bioactive glass ceramic particles as an alternative for mastoid obliteration: results in an animal model. *Otol Neurotol* 2002;23:657-660.
- Wilson J, Clark AE, Hall M, Hench LL. Tissue response to Bioglass endosseous ridge maintenance implants. *J Oral Implantol* 1993;19:295-302.
- Lovelace TB, Mellonig JT, Meffert RM, Jones AA, Nummikoski PV, Cochran DL. Clinical evaluation of bioactive glass in the treatment of periodontal osseous defects in humans. *J Periodontol* 1998;69:1027-1035.
- Froum SJ, Weinberg MA, Tarnow D. Comparison of bioactive glass synthetic bone graft particles and open debridement in the treatment of human periodontal defects. A clinical study. *J Periodontol* 1998;69:698-709.
- Mengel R, Soffner M, Flores-de-Jacoby L. Bioabsorbable membrane and bioactive glass in the treatment of intrabony defects in patients with generalized aggressive periodontitis: results of a 12-month clinical and radiological study. *J Periodontol* 2003;74:899-908.
- Dybvik T, Leknes KN, Boe OE, Skavland RJ, Albandar JM. Bioactive ceramic filler in the treatment of severe osseous defects: 12-month results. *J Periodontol* 2007;78:403-410.
- Ong MM, Eber RM, Korsnes MI, MacNeil RL, Glickman GN, Shyr Y, et al. Evaluation of a bioactive glass alloplast in treating periodontal intrabony defects. *J Periodontol* 1998;69:1346-1354.
- AboElsaad NS, Soory M, Gadalla LMA, Ragab LI, Dunne S, Zalata KR, et al. Effect of soft laser and bioactive glass on bone regeneration in the treatment of bone defects (an experimental study). *Lasers Med Sci* 2009;24:527-533.
- Tadjoedin ES, De Lange GL, Lyaruu DM, Kuiper L, Burger EH. High concentrations of bioactive glass material (BioGran) vs. autogenous bone for sinus floor elevation. *Clin Oral Implants Res* 2002;13:428-436.
- Galindo Moreno P, Avila G, FernÁndez Barbero JE, Mesa F, O'Valle Ravassa F, Wang HL. Clinical and histologic comparison of two different composite grafts for sinus augmentation: a pilot clinical trial. *Clin Oral Implants Res* 2008;19:755-759.
- Wang Z, Lu B, Chen L, Chang J. Evaluation of an osteostimulative putty in the sheep spine. *J Mater Sci: Mater Med* 2011;22:185-191.