



## Palatal Overgrowth Presenting as Oral Tuberculosis. A Case Report

Lanka Mahesh, Ashi Chugh, Sagrika Shukla and Varun Raj Kumar\*

Private Practice, The Specialist Clinic M5, Saket, New Delhi, India

\*Corresponding Author: Varun Raj Kumar, Private Practice, The Specialist Clinic M5, Saket, New Delhi, India.

Received: September 11, 2019; Published: October 17, 2019

### Abstract

According to the literature, extrapulmonary tuberculosis occurs in 10% to 15% of patients, out of which oral tuberculosis occurs in 0.05 - 5%. In the majority of cases, however, there is a primary pulmonary lesion. Reporting a case of gingival and palatal swelling as primary tuberculosis with no other sign or symptom elsewhere in the body. Tests such as histopathology, complete blood count and tuberculin (Mantoux) test confirmed the diagnosis. Based on clinical features, blood picture and histopathological findings patient was diagnosed with oral tuberculosis.

**Keywords:** Granulomatous Disease; Palatal Overgrowth; Inflammation; Tuberculosis

### Introduction

One of the oldest recorded human diseases is Tuberculosis (TB), dating back up 4,000 years ago, when Hippocrates made early records of signs and symptoms and unfortunately it still affects many causing one of the highest mortality rates among the infectious diseases, despite sincere efforts being taken worldwide towards its eradication via attenuated vaccine and antibiotics [1]. Rapid urbanization and development in the field of science showed decline of this disease, nonetheless statistics show that in every 15 seconds one someone dies of TB (over two million per year), and new cases of TB which emerge each year is approximately to be eight million [2].

Tuberculosis is a chronic granulomatous disease and mycobacterium tuberculosis (MTB) is the causative agent affecting almost every systems of the human body, such as pulmonary tuberculosis, which is the most common form. However, other organs such as oral cavity, lymphatic system, renal system, central nervous system, skeletal system, gastrointestinal system and hepatic system are also affected accounting for approximately 10% to 15% of all the patients [3,4].

### Clinical Symptoms in Relation to Oral Cavity

Pulmonary tuberculosis in majority of cases is the primary lesion, which may be residing in a dormant stage due to good immunity or may show healing by fibrosis or calcification [3]. In cases of poor immunity, spread takes place through local inoculation, hematogenous or lymphatics route [3]. Oral manifestations of TB are an uncommon form, mostly affecting organs with suboptimal conditions for bacillary growth [3]. Therefore, extrapulmonary tuberculosis generally has a slow progression with paucibacillary lesions and/or fluids [3].

One such extrapulmonary form is Orofacial tuberculosis, which is uncommon and has virtually become a forgotten disease [5]. It can be primary or secondary where the former is extremely rare, painless in most cases and usually occurs in young adults associated with caseation of the dependent lymph nodes [6,7]. In oral cavity it can occur at any site from alveolar bone, gingiva, buccal/lingual mucosa or tongue and can also be seen in lymph nodes of head, face or the neck, and also muscles of mastication. Orofacial tuberculosis is often overlooked because of its rarity and no specific pathognomonic signs [3].

Oral lesions account for 0.05 - 5% of total extra-pulmonary tuberculosis cases and have an association with the foci in the body elsewhere, along with palpable cervical lymph node [5,8]. The oral manifestations appear as superficial ulcers, nodules, patches, fissures, vesicles, granulomas, grade I or II gingival enlargements, and jaw lesions present with a radiographic image of TB osteomyelitis or simple bony radiolucency [5,8,9]. Ulcerative form of TB is the commonest of all lesions and if it's a tuberculoma or granuloma an underlying pulmonary disease is usually present [5,8,9]. Lesion is often painful, with no caseation of the dependent lymph nodes [8,9]. Common sites are tongue and gingiva followed by tooth sockets, soft palate, floor of mouth, lips and buccal mucosa. Primary gingival involvement is more common in children and adolescents than adults [5]. If it is present in the form of gingival enlargement or a swelling/tumor elsewhere in the oral cavity, its diagnosis becomes difficult as it simulates other pathologic conditions.

If orofacial TB is not the primary lesion then self inoculation from infected sputum is a usual occurrence. Direct inoculation commonly involves the gingiva, dental sockets and buccal folds [5]. It can also occur through a periodontal pocket, however intact oral mucosa is relatively resistant to TB bacilli penetration, and as well saliva has some inhibitory effect on mycobacteria [5] thus any breach in the mucosal lining may cause localization of organisms. Other predisposing factors include poor oral hygiene, dental extraction and leukoplakia [10].

### Case Report

A female patient aged 32 years reported with a chief complaint of swelling in palatal region since 3 - 4 years. The swelling was constant in shape and neither increased or decreased in size. There was no pain, tenderness in teeth, discharge or any other associated symptom. There were no aggravating or relieving factor associated with the mass. This was patient's first visit to the dental department and she had not taken any other medical opinion earlier. Patient did not have any systemic problems, no cough with expectoration, any history of dental trauma or any surgery in the affected area.

In personal history she revealed her uneducated status and that she brushed only once in daytime and had poor oral hygiene. Non-cervical lymphadenopathy was detected on extraoral examination. Intraoral examination showed poor oral hygiene, generalized chronic gingivitis, generalized bleeding on probing and class I gingival recession in relation to 11, 23, 24, 26 and 41. Generalized

grade I gingival enlargement, grade II enlargement in relation to 11, 12, 32 and grade III enlargement in relation to 31, 42 (Figure 1). On the palatal surface an oval shaped, firm, diffused, pale pink swelling of size 3X1cm, extending from distal of 13 to distal 23 was seen. It was non-tender, non fluctuant, without any discharge and any other associated symptom (Figure 2). Patient had generalized pockets and pseudo pockets in relation to mandibular anterior teeth. Rest of the oral cavity did not show any abnormality, except 46 which was grossly carious.

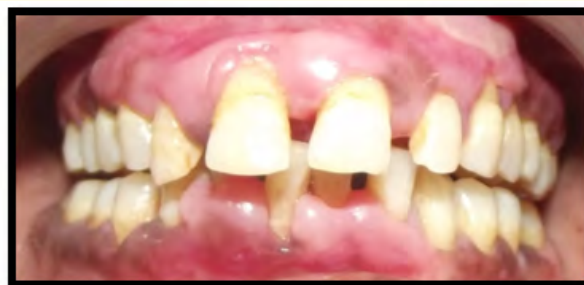

Figure 1: Frontal view.

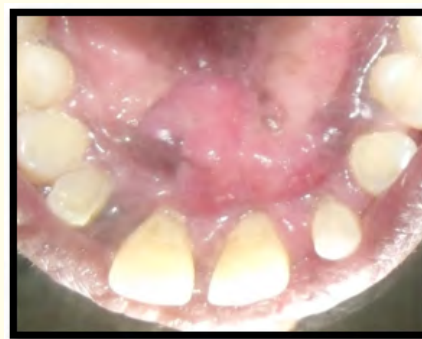
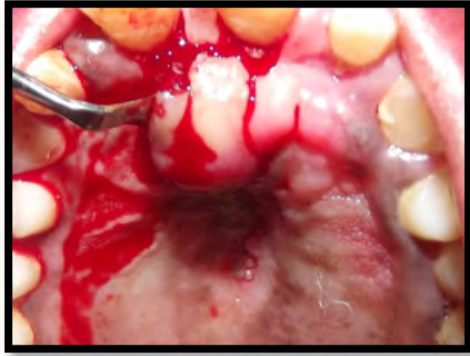
Figure 2: Occlusal view of the palatal swelling.

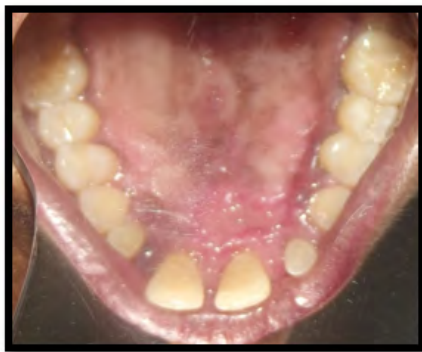Patient's signed consent was obtained for the blood examinations, surgical procedure and reporting of the condition for academic purposes. Complete blood count showed low haemoglobin, raised leukocyte count and elevated erythrocyte sedimentation rate (ESR), (Westergren method). An Excisional Biopsy (Figure 3) was performed on the palate and the excised tissue was sent for microscopic evaluation. Other investigations such as chest X-ray,

periodic acid-Schiff and Grocott-Gomori test for bacteria and fungi and tuberculin (Mantoux) test were also performed.



**Figure 3:** During the surgical procedure.

Routine post operative instructions were given to the patient. She was instructed to abstain from brushing and flossing around the surgical area until healing and to consume only soft food during the first week. Patient was prescribed with Chlorhexidine rinse 0.12% twice daily, morning and at night for a month and Tab. Ibuprofen 400 mg one tablet as per the need to control pain. Post-operatively at 15 days (Figure 4), healing was uneventful with no other side effect reported by the patient.

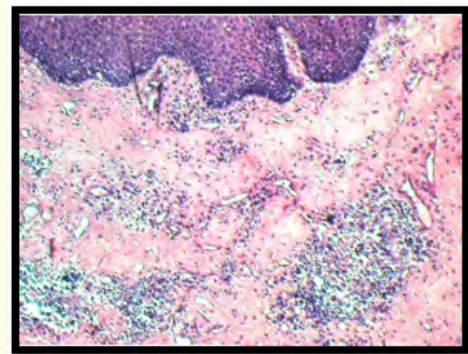


**Figure 4:** Healing at 15 days.

## Results

The blood picture showed raised leukocyte count and elevated erythrocyte sedimentation rate (ESR), (Westergreen method). On microscopic evaluation (Figure 5), bundles of collagen fibers

densely packed along with few areas of focal inflammatory cells. At one or two foci some multinucleated giant cells, peripheral lymphocytes and plasma cells were also seen. Numerous blood vessels with extravasated RBC's were also seen. Ziehl-Neelsen staining was positive for acid fast bacilli.



**Figure 5:** Histopathology of the lesion.

Chest X-ray did not show any abnormality. Periodic acid-Schiff and Grocott-Gomori stains for bacteria and fungi were negative. A tuberculin (Mantoux) test was positive, suggesting tubercular infection, which is also a confirmatory test for tuberculosis. Based on the clinical examination, blood tests and histological report patient was diagnosed with a case of gingival tuberculosis. She was further referred to the department of medicine for anti-tubercular treatment (ATT).

## Discussion

In 1991, the World Health Organization considered resurgence of tuberculosis as a global health problem, and death toll comes second only to HIV [11]. It most commonly occurs in developing countries where a vast population is uneducated and lives under poor socio-economic conditions. Tuberculosis causes granulomatous oral lesions which are rare and until and unless not diagnosed with secondaries elsewhere in the body, commonly chest, puts the clinician and the pathologist in dilemma regarding its diagnosis due to variety of possible etiologic diseases such as, foreign material, deep fungal infection, Crohn's disease, sarcoidosis, syphilis, Wegener's granulomatosis [12]. However, diagnosis is based on correlating clinical and microscopic evaluation that these conditions represent differently.

In sarcoidosis, symptoms such as dyspnea, dry cough, chest pain, fever, malaise, fatigue, weight loss are seen and along with oral mucosa it may also affect lungs, lymph nodes, skin, eyes and salivary glands [13]. In Lupus pernio, purplish plaques and erythema nodosum are also seen [13]. In Wegener's granulomatosis upper respiratory tract is involved along with nasal drainage, chronic sinus pain, nasal ulceration, congestion, fever and renal lesions are seen [13-16]. The most characteristic oral pathology is strawberry gingiva [13,14]. In Crohn's disease, gastrointestinal signs and symptoms such as, abdominal pain and cramping, nausea, weight loss, retarded growth, anemia, diarrhea, short stature are usually present [13,14]. In syphilis, a characteristic lesion, chancre develops either on the sexual organ or in the oral cavity or on the lips [14,17].

The granulomas of fungal infections and diseases like Sarcoidosis, Langerhans cell disease, Wegener's granulomatosis and tertiary syphilis when present on gingiva or alveolar mucosa have the usual tendency to destroy underlying bone [13-18]. In cases of involvement of large areas generalized enlargement of the affected site can be seen, which is also noticeable on the lips and tongue and gives a clinical picture as seen in cheilitis granulomatosa, Melkersson-Rosenthal syndrome and syphilitic glossitis [13,18]. Also, granulomas of autoimmune disorders such as, sarcoidosis, cheilitis granulomatosa and Crohn's disease are usually of small size and appear as multiple nodules/papules and sometimes give a cobblestone appearance to the mucosa when they cluster together [13,18]. Occurrence of any of the aforementioned signs or symptoms was not observed in the patient, and by correlating clinical and histological findings they were ruled out.

Differential diagnosis also included drug enlargement. Most common drugs which can cause gingival enlargement are cyclosporine, phenytoin, nifedipine and malignancy such as leukemia. However upon the medical history of the patient such conditions were ruled out. Also clinically, gingival enlargement did not show enlargement which occurs in patients suffering from leukemia which is bluish red with shiny surface and has a tendency for spontaneous hemorrhage or on slight irritation [19].

In the present case, patient reported with a long standing swelling of the palatal region, oral examination also revealed gingival enlargement, suggestive of oral tuberculosis. Literature has shown that oral tuberculosis, although rare but can also be present as the

primary lesion caused due to a breach in the oral mucosa, without causing any secondaries elsewhere in the body [8,9,12]. Clinically, the granulomas tuberculosis may be larger in size, more than 2 cm [14]. as was seen in this case. Chest X-ray did not show any abnormality, there was elevated ESR and the most important test, tuberculin (Mantoux) test was positive and Ziehl-Neelsen staining was positive for acid fast bacilli.

Thus keeping these aforementioned clinical and microscopic features into consultation this case was diagnosed as oral tuberculosis. As literature shows that the more virulent strain, induces smaller amounts of TNF- $\alpha$  and other inflammatory cytokines [20] thus according to our hypothesis this means that less virulent strain will cause increased amount of TNF- $\alpha$  and other cytokines resulting in increased tissue destruction and their deposition in the periodontal tissues increasing the swelling as was seen in the palatal region. Less virulent strain could plausibly also be the reason why there were no other abnormalities or secondaries observed elsewhere in the body such as lymph node involvement or presence of abnormality in chest or any other tubercular associated sign and symptom.

Tuberculosis, in many parts of the world still exists and infects humans at an alarming rate, including deaths. What we, as health care workers fail to observe is that this disease can infect any part of the body. Thus when a patient reports to a dental surgeon with no chest findings and continuous cough, we fail to comprehend with the fact that the swelling could be tubercular infection, especially when it's primary, as shown in this case report, which is a rare occurrence. Thus, dental surgeons should be very careful in examining the patient and universal infection control measures should be followed by the health worker while treating the patient.

## Conclusion

Primary oral tubercular lesion is a rare entity and simulates many other gingival enlargements such as condition enlargements, drug-induced enlargement, leukemia and various other systemic conditions. Not considering it in the differential diagnosis of oral lesions may cause difficulty in its correct diagnosis. This may cause spread of the disease among the family members of the patient and puts the dental surgeon at risk of contracting the disease. Thus clinical features, blood picture and histopathological findings should be correlated for efficacy resulting in improved therapeutic efficiency.

## Acknowledgement

Nil.

## Conflict of Interest

None declared.

## Bibliography

1. Smith I. "Mycobacterium tuberculosis Pathogenesis and Molecular Determinants of Virulence". *Clinical Microbiology Reviews* 16 (2003): 463-496.
2. Kaye K and Frieden TR. "Tuberculosis control: The relevance of classic principles in an era of acquired immunodeficiency syndrome and multidrug resistance". *Epidemiologic Reviews* 18 (1996): 52-63.
3. Andrade NN and Mhatre TS. "Orofacial Tuberculosis — A 16-Year Experience With 46 Cases". *Journal of Oral and Maxillofacial Surgery* 70 (2012): 12-22.
4. Umadevi M, et al. "Primary Tuberculous Osteomyelitis of the Mandible". *Asian Journal of Oral and Maxillofacial Surgery* 15 (2003): 208-213.
5. Rodrigues G, et al. "Primary Isolated Gingival Tuberculosis". *The Brazilian Journal of Infectious Diseases* 11 (2007): 172-173.
6. Nwoku LA, et al. "Primary tuberculous osteomyelitis of the mandible". *Journal of Oral and Maxillofacial Surgery* 11 (1983): 46-85.
7. Smith WH, et al. "Intraoral and pulmonary tuberculosis following dental treatment". *Lancet* 1 (1982): 842-844.
8. Sezer B, et al. "Oral mucosal ulceration: A manifestation of previously undiagnosed pulmonary tuberculosis". *Journal of the American Dental Association* 135 (2004): 336-340.
9. Eng HL, et al. "Oral tuberculosis". *Oral Surgery, Oral Medicine, Oral Pathology, and Oral Radiology* 81 (1996): 415-419.
10. Gupta A, et al. "Primary lingual tuberculosis: A case report". *The Journal of Laryngology and Otology* 112 (1998): 86-87.
11. Lin PL and Flynn JL. "Understanding latent tuberculosis: A moving target". *Journal of Immunology* 185 (2010): 15-22.
12. Karthikeyan BV, et al. "Primary Tuberculous Gingival Enlargement: A Rare Entity". *Journal of the Canadian Dental Association* 72 (2006): 645-648.
13. Sivapathasundharam B. "Allergic and immunologic diseases of the oral cavity". In: Rajendran R, Sivapathasundharam B (eds.) *Shafer's textbook of oral pathology*. 7th ed, New Delhi: Elsevier, (2012): 666-682.
14. Neville BW, et al. "Oral and Maxillofacial Pathology". Elsevier, New Delhi (2005).
15. Devaney K, et al. "Interpretation of head and neck biopsies in Wegener's granulomatosis". *The American Journal of Surgical Pathology* 14 (1990): 555-564.
16. Lilly J, et al. "Wegener's granulomatosis presenting as oral lesions. A case report". *Oral Surgery, Oral Medicine, Oral Pathology, and Oral Radiology* 85 (1998): 153-157.
17. B Sivapathasundharam and N Gururaj. "Bacterial infections of the oral cavity". In: R. Rajendran, B. Sivapathasundharam (eds.) *Shafer's textbook of oral pathology*. 7th ed, Elsevier, New Delhi, (2012): 317-338.
18. R Winnie and DM DeLuke. "Melkersson-Rosenthal syndrome: Review of the literature and case report". *International Journal of Oral and Maxillofacial Surgery* 21 (1992): 115-117.
19. FA Carranza and EL Hogan. "Gingival Enlargement". In: M.G. Newman, H.H. Takei, F.A. Carranza (eds). *Carranza's Clinical Periodontology*, 9th edition, Philadelphia, PA, Saunders (2002): 279-297.
20. Manca C, et al. "Virulence of a Mycobacterium tuberculosis clinical isolate in mice is determined by failure to induce Th1 type immunity and is associated with induction of IFN-alpha/beta". *Proceedings of the National Academy of Sciences* 98 (2001): 5752-5757.

**Volume 3 Issue 11 November 2019**

**© All rights are reserved by Varun Raj Kumar, et al.**