

# Sinus augmentation with simultaneous removal of antral polyp

## Abstract

Antral polyps are the most common pathologies found in maxillary sinus. If asymptomatic, it can be left untreated but if symptomatic and is encountered during posterior maxillary rehabilitation procedures like sinus augmentation procedures, it has to be treated preoperatively through FESS procedure by otolaryngologist or may be treated intra operatively during sinus elevation procedure as the case presented here.

**Keywords:** sinus, polyp, sinus floor elevation, bone graft

Volume 11 Issue 5 - 2019

Lanka Mahesh,<sup>1</sup> David Morales Schwartz,<sup>2</sup> Varun Raj Kumar,<sup>3</sup> Sagrika Shukla,<sup>4</sup> Saurabh Juneja<sup>5</sup>

<sup>1</sup>M.B.A the specialist clinic, India

<sup>2</sup>D.M.D private practice, Spain

<sup>3</sup>The specialist clinic, India

<sup>4</sup>Department of periodontics, Aiiims, India

<sup>5</sup>Department of oral Pathology, ITS Dental College, UP, India

**Correspondence:** Varun Raj Kumar, Mds, The Specialist Clinic, M5 Saket, New Delhi 110017, India, Ph. 7042277554, Email drvarunrajkuma@gmail.com

**Received:** September 24, 2019 | **Published:** October 14, 2019

**Abbreviations:** NP, antral polyp; ASA, aspirin sensitive asthma; AERD, aspirin exacerbated respiratory disease; CBCT, cone beam computed tomography

## Introduction

An implant has become an integral part in the treatment of replacement of missing teeth. A well placed implant, following all the guidelines of its placement will osseointegrate and will provide functional and esthetic stability to the patient. Stating this also means that, apart from following surgical protocol, presence of good quality bone is paramount for implants to osseointegrate. Development in implantology has overcome this clinical limitation and implants can now also be placed in thin alveolar bones through cortical split, in maxillary sinus through direct and indirect sinus lift procedures also in presence of maxillary sinus pathology such as a polyp, cysts, etc.

Implant placement in maxillary sinus is a well established procedure and in case of deficient available bone, height of the alveolar ridge is increased to accommodate the implant and improve bone quality. Antral polyps are the most common pathologies found in maxillary sinus occurring due to chronic sinusitis where stagnation of mucous takes place. Apart from polyps there are other pathologies which can be seen in the maxillary sinus such as papillomas, schwannomas, osteomas, mucous retention cysts, etc.

Antral polyposis (NP) is a chronic inflammatory disease and has been known for more than 3000 years.<sup>1</sup> A polyp is the prolapse of inflamed mucosa within the nose, and can be pediculated with a smooth surface, gelatinoid, spherical, or in the shape of grape.<sup>2</sup> Allergy, infection, enzyme abnormality, mechanical obstruction, autonomic imbalance, abnormal transepithelial ion transport, and epithelial rupture are the proposed mechanisms that can cause a polyp.<sup>3</sup> Allergic and inflammatory theories regarding the etiopathogenesis are particularly emphasized. Aspirin-sensitive asthma (ASA), recently it has been termed as Aspirin-Exacerbated Respiratory Disease (AERD), also known as “aspirin triad” (antral) polyposis, asthma, and

sensitivity to aspirin) is a well-recognized clinical entity.<sup>2</sup> It is often also observed with other disorders such as cystic fibrosis, asthma, Kartagener’s syndrome, Young syndrome and diabetes mellitus.<sup>2</sup> Even after medical and surgical treatment options, relapses have been reported.<sup>2</sup> Polyps are mainly located in the middle meatus, maxillary sinus, frontal recess; and originate from the nasal mucous membrane ostia in the paranasal sinus.<sup>4,5</sup>

## Case report

A 55-year-old female reported to the clinic with the chief complaint of missing teeth in upper left quadrant. On intra-oral examination left upper 1st molar was missing and fractured root stump for 2nd molar was seen. On discussing treatment options and since the patient was medically fit, implants was planned for missing tooth with removal of root stump. Patient was advised with Cone beam computed tomography (CBCT) scan for the concerned area. On receiving CBCT images (Figure 1), a lesion was noted within the sinus and incidental finding of an impacted 3rd molar was also seen. The residual bone height was found to be in the range of 3-5mm. Therefore the patient was advised a sinus floor elevation procedure with delayed implant placement. Informed consent for the same was taken from the patient.

A full thickness flap was elevated (Figure 2&3) and access was gained through the lateral of the sinus. The sinus window preparation completed with diamond peizo surgical tip (Acteon France) (Figure 4). The created window (Figure 5) was rotated inside (Figure 6), subsequently sinus curettes were used to gently elevate the schneiderian membrane till the complete lift was clinically evident. Bone graft material (Bioss, Geistlich, SUI) was packed (Figure 7). The root stump of left upper 2nd molar was extracted along with the lesion from the antrum (Figure 8&9). A collagen membrane (creos, nobel biocare, CA, USA) (Figure 10) was placed over antrostomy (Figure 11) and wound was closed with 3-0 polyamide suture (Figure 12). The lesion was sent for histo-pathology and was reported to be a antral polyp. Post-operative healing was uneventful (Figure 13).

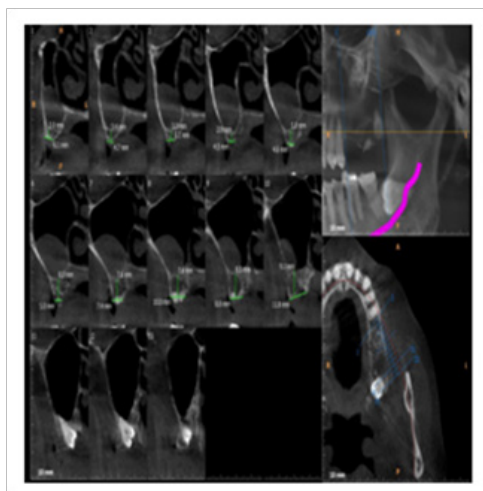


Figure 1 Preoperative CBCT.

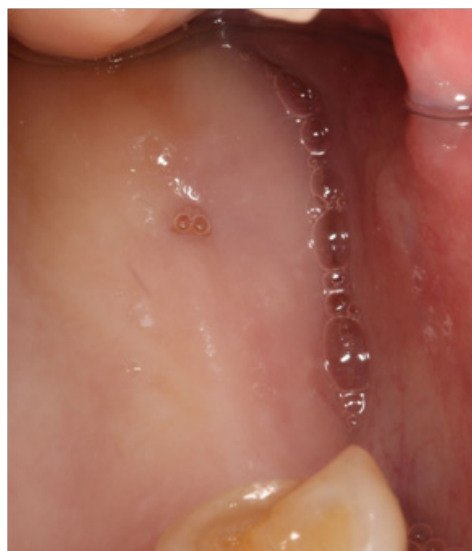

Figure 2 Intra oral view.

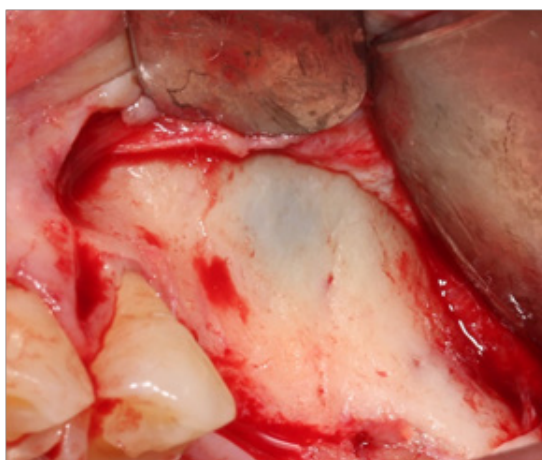


Figure 3 Flap elevation.

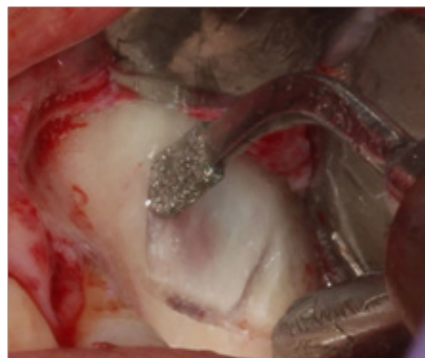


Figure 4 Window preparation with piezo.

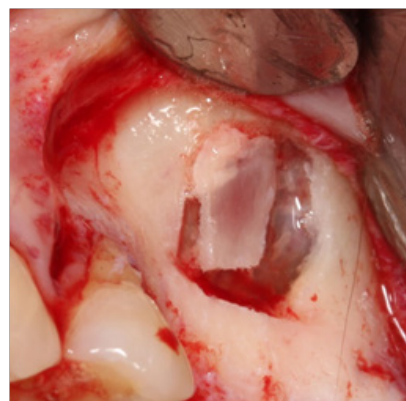


Figure 5 Sinus window.

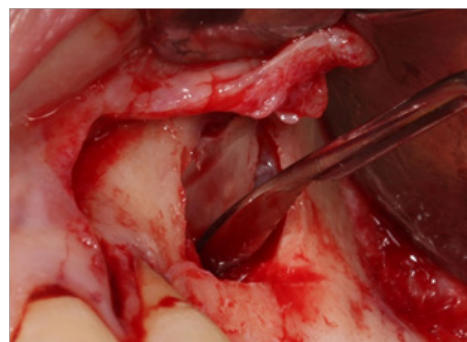

Figure 6 Buccal window rotated and made as new sinus roof.

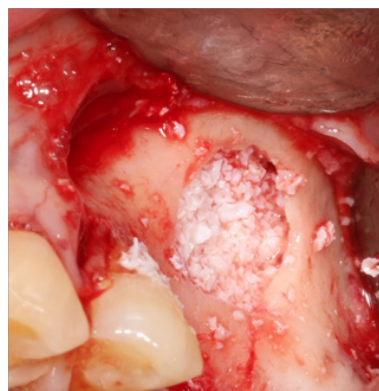
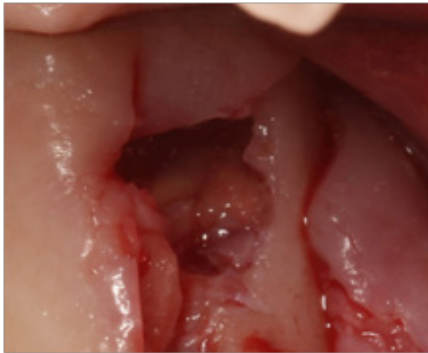
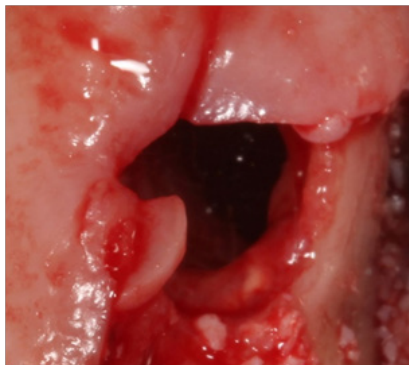


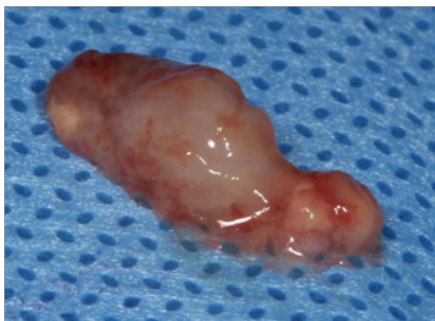Figure 7 Bone graft placed.



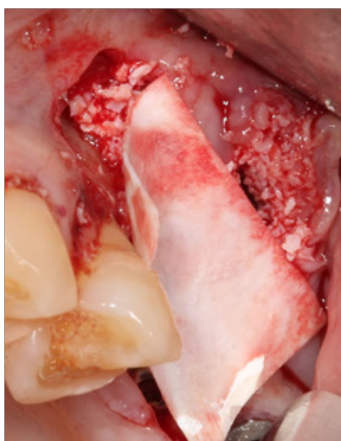
**Figure 8** Antral polyp visible through extraction socket.



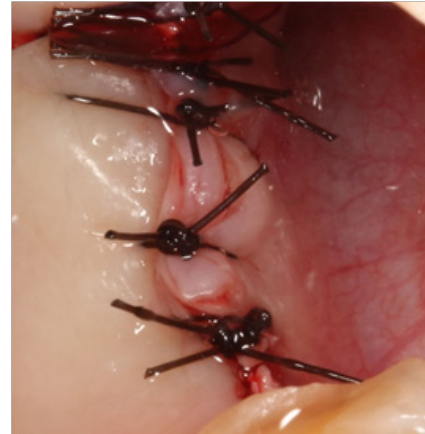
**Figure 9** Antral polyp removed.



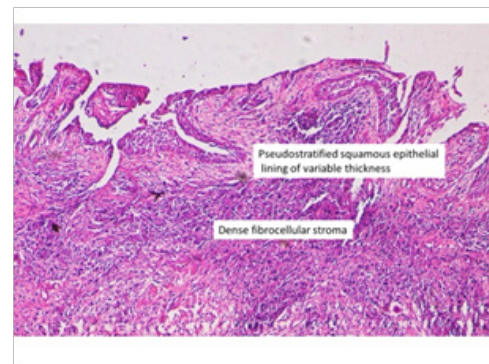
**Figure 10** Antral polyp.



**Figure 11** Collagen membrane placed.



**Figure 12** Wound closure.



**Figure 13** Histology depicting antral polyp.

## Discussion

Rehabilitation of posterior maxilla for placement of dental implants has become a routine procedure with reliable long-term results.<sup>6-8</sup> However certain local conditions can become absolute or relative contraindication for placement of implants. A grafting procedure generally does not interfere with sinus functions when performed on a healthy sinus,<sup>9-11</sup> however when performed on unhealthy sins will lead to fluid stagnation and bacterial overgrowth leading to exacerbated sinusitis.<sup>12</sup> Moreover any pathology such as a cyst or a polyp will pose a difficulty in sinus elevation. According to Ziccardi and Betts,<sup>13</sup> the presence of maxillary cysts is an absolute contraindication for sinus grafting, and so is a maxillary sinus antral pseudocysts.

Radenne et al.,<sup>14</sup> found that nasal polyps, besides causing nasal obstruction, hyposmia, and recurrent infection, impaired the quality of life more than did perennial allergic rhinitis. Thus a polyp can get infected and can cause failure in the augmentation procedure along with a failed implant procedure. Clinical as well as experimental studies indicate that nasal polyp formation and growth are activated and perpetuated by an integrated process of mucosal epithelium, matrix, and inflammatory cells, which, in turn, may be initiated by both infectious and noninfectious inflammation.<sup>15</sup> This underlying pathology may lead to increased interstitial fluid pressure and obstruct blood flow in nasal polyps, resulting in edema and distension of stroma. If nasal polyps obstruct sinus drainage, subsequent infection can cause more venous stasis and mucosal edema, leading to a self-perpetuating cycle.<sup>16</sup> A chronic recurrent sinusitis, with or without



polyposis that disrupts mucociliary clearance and is unresponsive to medical or surgical treatment becomes an absolute contraindication.<sup>12</sup> Other than this a polyp can be simultaneously removed along with the implant placement.<sup>17</sup>

According to the literature, maxillary sinus cysts/other pathologies are a frequent diagnosis on radiographs with a prevalence of up to 21%<sup>18</sup> and traditionally been treated by a Caldwell-Luc operation or endoscopic sinus surgery with a recommended healing period of at least 6-12 months before further surgical treatment can be performed.<sup>18-20</sup> Due to time constraints, undergoing through trauma of repetitive surgical procedure and cost factor involved a polyp can be removed along with the sinus augmentation process. Surgical removal of polyp will also lead to the removal of sinus lining, however, the sinus lining has a very high and rapid regenerative capacity after trauma or surgical removal.<sup>21</sup> Experimental operative removal of mucous lining in rabbits show regeneration and reepithelialization within 2 weeks,<sup>22</sup> meaning even if the membrane is removed it will reepithelialize within 2-3 weeks, posing no threat in the process of graft consolidation.

Several authors such as Tang et al.,<sup>23</sup> and Mardinger et al.,<sup>24</sup> reported sinus augmentation and implant placement even in the presence of antral pseudocyst. Tang et al.,<sup>23</sup> also reported good osseointegration even after 3 months of the procedure done in presence of antral pseudocyst and concluded that it may not be necessary to remove a sinus cyst before or during the sinus augmentation operation if the patient does not have any symptoms and the cyst is not large. Wang and Kung<sup>25</sup> successfully performed sinus augmentation procedure in 2 patients, one with retention cyst and other with bilateral thickened Schneiderian membrane, without subsequent complications in the sinuses and grafted sites. These studies show that if an implant can be placed and achieve osseointegration in the presence of a cyst, it can be definitely placed after polyp removal. Also, there is vast literature available stating that the treatment of sinus cysts/mucocele/polyp consists of complete removal of the cyst with simultaneous bone grafting of the cavity.<sup>17</sup>

## Conclusion

Data presented at the sinus consensus conference confirms high predictability of this procedure.<sup>26</sup> The important factor being good presence of bone. This criterion can be achieved even after polyp removal through graft placement. In spite of advancements there still remain certain pathologies where implant placement in posterior maxilla is an absolute contradiction, which can be hopefully addressed in future.

## Acknowledgments

None.

## Conflict of interests

The authors declare that there is no conflict of interests regarding the publication of this paper.

## Funding details

None.

## References

1. Akbay E, Özgür T, Çokkeser Y. Is there any relationship between the clinical, radiological and histopathologic findings in sinonasal polyposis? *Turk Patoloji Derg.* 2013;29:127-133.
2. Akba E, Özgür T, Çokkeser Y. Is there any relationship between the clinical, radiological and histopathologic findings in sinonasal polyposis? *Turk patoloji derg.* 2013;29:127-133.
3. Assanasen P, Naclerio RM. Medical and surgical management of nasal polyps. *Curr Opin Otolaryngol Head Neck Surg.* 2001;9:27-36.
4. Mygind N, Dahl R, Bachert C. Nasal polyposis, eosinophil dominated inflammation, and allergy. *Thorax.* 2000;55 Suppl 2:S79-S83.
5. Larsen PL, Tos M. Origin of nasal polyps: An endoscopic autopsy study. *Laryngoscope.* 2004;114:710-719.
6. Albrektsson T, Zarb G, Worthington P, et al. The long term efficacy of currently used dental implants: a review and proposed criteria of Success. *Int J Oral Maxillofac Implants.* 1986;1:11-25.
7. Adell R, Eriksson B, Lekholm U, et al. A long term follow-up study of osseointegrated implants in the treatment of totally edentulous jaws. *Int J Oral Maxillofac Implants.* 1990;5(4):347-359.
8. Leonhardt A, Grondahl K, Bergstrom C, et al. Long term follow-up of osseointegrated titanium implants using clinical, radiographic and microbiological parameters. *Clin Oral Implants Res.* 2000;13(2):127-132.
9. Timmenga NM, Raghoobar GM, Boering G, et al. Maxillary sinus function after sinus lifts for the insertion of dental implants. *J Oral Maxillofac Surg.* 1997;55(9):936-939.
10. Peleg M, Chaushu G, Mazor Z, et al. Radiological findings of the post-sinusitis lift maxillary sinus: a computerized tomography follow-up. *Periodontol.* 1999;70(12):1564-1573.
11. van Den Berg JP, Ten Bruggenkate CM, Disch FJ, et al. Anatomical aspects of sinus floor elevations. *Clin oral implants res.* 2000;11(3):256-265.
12. Chiapasco M, Rosenlicht JL, Ruggiero SL, et al. Contraindications for sinus graft procedures. In: Jensen OT, editor. *The sinus bone graft*, 2nd ed. Illinois, Quintessence, 2006. p. 87-101.
13. Ziccardi VB, Betts NJ. Complications of maxillary sinus augmentation. In: Jensen OT, editor. *OT Jensen The sinus bone graft*. Carol Stream, IL: Quintessence publishing Co, 1999. p. 201-08.
14. Radenne F, Lamblin C, Vandezande LM, et al. Quality of life in nasal polyposis. *J Allergy Clin Immunol.* 1999;104(1):79-84.
15. Norlander T, Bronnegard M, Stierna P. The relationship of nasal polyps, infection, and inflammation. *Am j rhinol.* 1999;13(5):349-353.
16. Assanasen P, Naclerio RM. Medical and surgical management of nasal polyps. *Curr Opin Otolaryngol Head Neck Surg.* 2001;9(1):27-36.
17. Pikos MA. Complications of maxillary sinus augmentation. In: Jensen OT, editor. *The sinus bone graft* 2nd ed. Illinois, quintessence, 2006. p. 103-114.
18. Beaumont C, Zafiroopoulos GG, Rohmann K, et al. Prevalence of maxillary sinus disease and abnormalities in patients scheduled for sinus lift procedures. *J periodontol.* 2005;76(3):461-467.
19. Atherino CC, Atherino TC. Maxillary sinus mucopyoceles. *Arch otolaryngol.* 1984;110:200.
20. Busaba NY, Salman SD. Maxillary sinus mucocoeles: Clinical presentation and long-term results of endoscopic surgical treatment. *Laryngoscope.* 1999;109(9):1446-1449.
21. Stammberger H. *Functional endoscopic nasal and paranasal sinus surgery*. Philadelphia, BC Decker, 1991.
22. Forsgren K, Stierna P, Kumlien, et al. Regeneration of maxillary sinus mucosa following surgical removal: experimental study in rabbits. *Ann otol rhinol laryngol.* 1993;102(6):459-466.
23. Tang ZH, Wu MJ, Xu WH. Implants placed simultaneously with maxillary sinus floor augmentations in the presence of antral pseudocysts: a case report. *Int j oral maxillofac surg.* 2011;40(9):998-1001.

24. Mardinger O, Manor I, Mijiritsky E, et al. Maxillary sinus augmentation in the presence of antral pseudocyst: A clinical approach. *Oral surg oral med oral pathol oral radiol endod.* 2007;103(2):180–184.
25. Wang TC, Kung S. Sinus augmentation into sites with mucosal pathologies of maxillary sinus. *J taiwan periodontol.* 2008;13:327–337.
26. Jenson OT, Shulman LB, Block MS, et al. Report of the sinus consensus conference of 1996. *Int j oral maxillofac implants.* 1998;13:11–45.