

IMMEDIATE IMPLANT PLACEMENT IN POSTERIOR MAXILLA

LANKA MAHESH¹, SAGRIKA SHUKLA², SANDEEP SINGH³ & KULDEEP SINGH⁴

¹Implantologist, Private Practice, New Delhi, India

²Senior Resident, Department. of Dentistry, All India Institute of Medical Sciences, Rishikesh, Uttarakhand, India

³Private Practice, Allahabad, India

⁴Senior Lecturer, Department of Endodontics, R And R Dental College, Udaipu, India

ABSTRACT

Immediately after tooth extraction, 50 percent of bone loss occurs resulting in delayed implant placement, making patient to undergo advanced bone grafting procedure which increases the time and cost of the treatment. Immediate implant placement is an easy and affordable solution providing functional comfort to the patient.

KEY WORDS: Immediate Implant, Bone Grafting, Maxillary Ridge & Posterior Maxilla

Received: Jan 11, 2018; **Accepted:** Jan 31, 2018; **Published:** Feb 22, 2018; **Paper Id.:** IJDRDJUN20181

INTRODUCTION

Immediately after tooth extraction, bone undergoes remodeling wherein, the maximum amount of bone is lost during the first 6 months of extraction^{1,2}. However, this process is rapid in cases of posterior maxilla, because of the bone type. As a result, placement of an immediate implant in the posterior maxilla becomes paramount. The advantage of this technique is that it reduces treatment time and further bone loss decreasing the chances of advanced bone grafting procedures and thus the cost of the treatment.

Many authors, however suggest that the best treatment is the delayed approach of implant placement³, which increases the quality of the bone and gives the advantage of placement of implant in its correct position. With immediate implants, the option of its placement is in the palatal socket off-axis or modification of the palatal socket, or in the interdental septa which shows better results than the delayed approach after osseous healing⁴.

In spite of all the precautions taken, bone grafting is often required for immediate implants places, more so in cases of posterior maxilla and also to cover jumping distance. There are various graft materials which have been successfully used for the same purpose, however Calcium Phosphosilicate Putty (NovaBone Dental Putty) has shown satisfactory and superior results as compared to other bone grafts⁵. Novabone® (NB) is an alloplastic bone graft material. It is a third generation bioactive glass derived graft substitute in a putty format which makes its placement at the site easy as the gel serves to hold the glass particles in a cohesive mass⁶. This graft material has the ability to adhere to normal bone, which helps in its remodeling as well as enables hemostasis⁷.

CASE SERIES

All patients who opted for immediate implant placement were healthy without any medical condition and non-smokers. Most of the patients had grossly destructed/root canal failed/fractured crown in maxillary posterior teeth which needed extraction (figure 1 and 2). Prior to the treatment, patients were consulted and a signed consent was taken from

them.

166 immediate implants (all implants used were TOP DM ,Bioner Spain) were placed in 107 patients. 122 Implants were of 5mm diameter and 42 implants were of 4 mm diameter according to the anatomic site, keeping aseptic surgical protocol in mind and following implant osteotomy guidelines (figure 3). Patients were regularly followed up for any changes in the peri-implant soft tissue for a period of 3 years (figure 4 and 5). At the end of three years, 6 implants were lost. For the rest of the patients healing was uneventful.

DISCUSSIONS

Delayed implant placement has many disadvantages such as cost, time, mastication problems for the patient, and bone loss. Thus, immediate implant treatment option is more advantageous as it reduces the treatment time. However, Luchetti et al⁴ also states that the healed bone is often softer as compared to the bone during extraction⁴ thus delayed implant should be considered in cases of an active infection or cases where it is difficult to achieve primary stability.

During implant placement, there is often some space present in between the implant placed and the osteotomy prepared, known as the jumping distance⁸. This may interfere with healing, as a result a bone graft is used to promote healing. As aforementioned, Novabone[®] putty has shown better results as compared to other bone grafts⁵ thus, authors used the same bone graft for all the immediate implant cases reported in the manuscript. Novabone[®] induces release of chemicals in the form of ionic dissolution products, or growth factors such as bone morphogenetic protein (BMP) at controlled rates, by diffusion or network breakdown that activates the cells in contact with the stimuli⁹. It also activates several families of gene such as CD44, IGF2, MMP2, 60S ribosomal protein L6¹⁰. According to Pietrokovski¹¹, dense trabecular bone is formed in extraction sockets when Novabone[®] putty is used.

In another clinical study by Dimaira¹² of immediate grafting prior to implant placement showed immediate postoperative radiograph showed excellent adaptation of NovaBone Dental Putty to the implant surface. Six-week post-operative radiograph revealed a good trabecular pattern around the implant indicative of osseous regeneration and the nine month post-operative radiograph showed an excellent trabecular pattern indicative of complete resorption of the putty and successful bone regeneration.

CONCLUSIONS

Immediate implant placement is a better treatment option as compared to delayed implant placement. Although the authors report a loss of 6 implants which can be attributed to various reasons, the overall healing of all the implants placed was satisfactory and uneventful.

REFERENCES

1. Bhaskar SN. *Orban's oral histology and embryology (11th ed)*. St Louis, Mo: CV Mosby; 239-59.
2. Carlsson GE, Bergman B, Hedegard B. *Changes in contour of the maxillary alveolar process under immediate dentures. A longitudinal clinical and x-ray cephalometric study covering 5 years. Acta Odontol Scand* 1967;25:45-75.
3. Luchetti CG, Kurtzman GM, Kitrilakis AE, Ostrowicz DI. *Immediate implant placement in maxillary molars using septa dilatation with threaded expanders: 3 years follow-up and use of the technique in complex cases. Int J Oral Implantol Clin Res* 2012;3:138-145.

4. Luchetti C, Kitrilakis A. immediate implant placement in the inter-septal bone of maxillary molars. *J Indian Soc Oral Implantol* 2006;3:1-5.
5. Gonshor A, Lanka M, Saroff SA, Joachim FPC, Charon JA. Histologic and clinical evaluation of bioactive calcium phosphosilicate bone graft material in post extraction alveolar sockets. *J Implant Adv Clinical Dent* 2011;3:21-31.
6. Cho YR, Gosain AK. Biomaterials in craniofacial reconstruction. *Clin Plast Surg* 2004;31:377-85.
7. Sagrika Shukla, Vidhi Gupta & Ashi Chug, One Year Follow Up of an Iatrogenic Root Perforation Treated With Mineral Trioxide Aggergate (MTA) and Vertical Bone Loss Grafted with Novabone Bone Graft Plus Platelet Rich Plasma (PRP), *International Journal of Dental Research & Development (IJDRD)*, Volume 6, Issue 3, May – June 2016, pp. 1-12
8. Ghoreishian SM, Jamalpoor M. Clinical, radiographic and histologic comparison of ridge augmentation with bioactive glass alone and in combination with autogenous bone graft. *Dental Research J* 2006;2:1-9.
9. Botticelli D, Berglundh T, Buser D, Lindhe J. the jumping distance revisited: as experimental study in the dog. *Clin Oral Implants Res* 2003;14:35-42.
10. Hench LL. The story of Bioglass. *J Mater Sci: Mater Med* 2006;17:967-78.
11. Hu Yong-Cheng, Zhong Ji-Pin. Osteostimulation of bioglass. *Chin Med J* 2009;122:2386-89.
12. Pietrokovski J. The bony residual ridge in man. *J Prosthet Dent* 1975;34:456-62.
13. Dimaira M. Novel way of using nova bone dental putty in a fresh extraction socket prior to implant placement.

Figure Legend

Figure 1: Fractured tooth

Figure 2: Tooth after extraction

Figure 3: Immediate implant placed extraction socket

Figure 4: Soft tissue healing around implant at 4 months

Figure 5: Implant follow-up at the end of 3 years.

APPENDICES

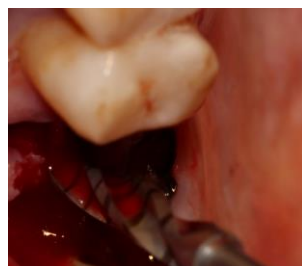

Figure 1

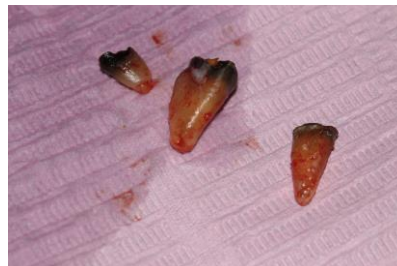

Figure 2

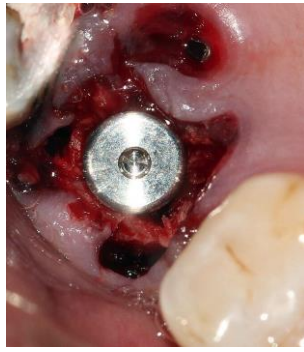

Figure 3

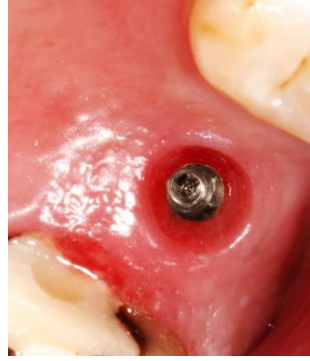


Figure 4

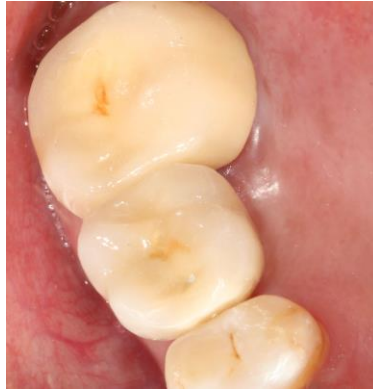

Figure 5

