



ORIGINAL RESEARCH PAPER

Dental Science

IMMEDIATE MAXILLARY POSTERIOR IMPLANTS AND SIMULTANEOUS BONE AUGMENTATION USING HA-BETA TCP AS GRAFTING MATERIAL

KEY WORDS:

Dr. Lanka Mahesh*

BDS MBA, Private Practice, The Specialist Clinic, New Delhi, India *
Corresponding Author

Tanvi Paliwal

MDS, Private Practice, The Specialist Clinic, New Delhi, India

Dr. Zara Dhawan

BDS, Private Practice, The Specialist Clinic, New Delhi, India

INTRODUCTION

Loss of bone often leads to aesthetic failures in later stages. It is crucial to build lost bone for aesthetics and for proper osseointegration of the implant.

Bone augmentation techniques may be used for the applications of extraction socket defect grafting, horizontal ridge augmentation, vertical ridge augmentation, and sinus augmentation amongst other procedures.

After extraction of the tooth, loss of alveolar ridge occurs. This leads to a poor esthetics and impair functional and structural facets of treatment Bone has two layers, namely the outer cortical layer and the inner cancellous layer.

The dense haversian systems of cortical bone gives its skeletal strength. Placed between the cortices is a three-dimensional lattice network of trabeculae that conducts itself as a reservoir for active bone metabolism. This bony architecture is dynamic with a continuous remodeling to repair and shape the bone to ensure renewal of form and function A number of strategies are there for augmenting depending on the quantity of the available deficient alveolar bone.

These comprise of GBR, particulate grafting materials, onlay block grafting techniques, distraction osteogenesis, ridge split techniques, the future applications of molecular factors to stimulate the rate of bone formation, and in severe defects, an amalgamation of these techniques can be used, Classification of bone grafts based on material groups: Allograft-based bone graft involves allograft bone, used alone or in combination with other materials e.g., Grafton (Biohorizon, USA), Puros (Zimmer, USA) Factor-based bone graft contain natural and recombinant growth factors, are used alone or in union with other materials such as transforming growth factor-beta (TGF-beta), platelet-derived growth factor (PDGF), fibroblast growth factors (FGF), and bone morphogenic protein (BMP). Cell-based bone grafts use cells to generate new tissue alone or are added onto a support matrix, for example, mesenchymal stem cells. Ceramic-based bone graft substitutes include calcium phosphate, calcium sulfate, and bioglass used alone or in combination. Polymer-based bone graft uses degradable and nondegradable polymers alone or in combination with other materials.

Bone graft used in this case was Qualybone from Portugal. Granule size used 0.5 - 1.0mm. This bone graft is a 100% synthetic porous ceramic. Because of its configuration in mesh format has a high porosity, facilitating the proliferation of bone cells into the empty spaces. This format offers an excellent mechanical strength.

It has Excellent characteristics of opacity, allowing the radiological monitoring during the bone regeneration.

Cell adhesion is observed after 5 days. It also Facilitates an effective process of vascularization after intervention. It

Induces regeneration and bone growth by stimulating the proliferation and differentiation of osteoblasts.

The TCP Qualybone is composed of 100% of tricalcium phosphate (BETA-TCP) and is absorbed between 1 to 6 months. The Qualybone BCP is composed of 75% hydroxyapatite and 25% tricalcium phosphate (BETA-TCP) and is absorbed between 6 to 24 months.

Case Report

A male in his mid-fifties came to the dental office complaining of missing teeth in both left and right back upper teeth region and wished to replace them.

On examination, multiple root stumps were seen in the maxillary right region He had no relevant medical history. (Figure 1 A and B)

After administration of local anesthesia (2% lidocaine with 1:80,000 epinephrine) a full thickness flap was raised extending from 14 region till 16 region using a 15C blade followed by extraction of root stumps. (Figure 2)

Bioner Implants (Spain) size DM-410 were placed in 14,15,16 region. (Figure 3)

After placement of implants, Qualy Bone tricalcium phosphate (Portugal) granule size 0.5-1.0mm 5cc was packed into the defects and the jumping distance. (Figure 4A and 4B) Ossix Volumax collagen scaffold (Datum Dental, Israel) 15mm X25mm was placed and the wound was closed using nylon 3-0 sutures. (Figure 5) Haemostasias was achieved.

After 3 months second stage surgery was done to expose the implants, RFA reading was taken at this point using a penguin device. (Figure 6A and 6B)

14-74
15-77
16-80
followed by placement of gingival former. The wound was closed using cytoplast PTFE 4-0 sutures. (Figure 7)

Open tray impression was taken after 10 days once the gingival tissue healed around the gingival former (Figure 8)

Screw retained prosthesis was given to the patient. (Figure 9 A and B)

CONCLUSION

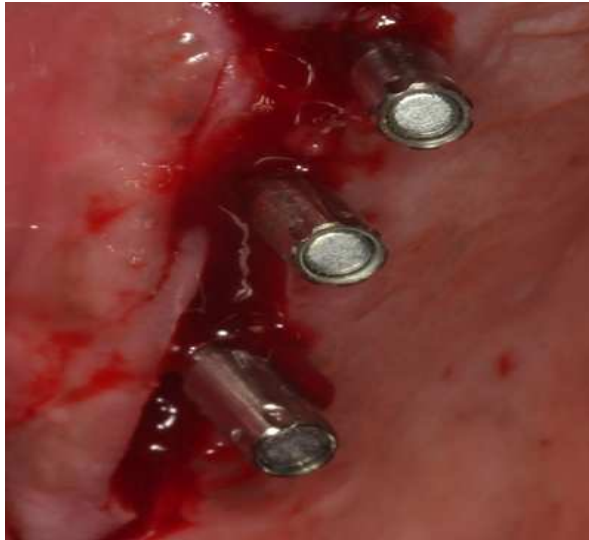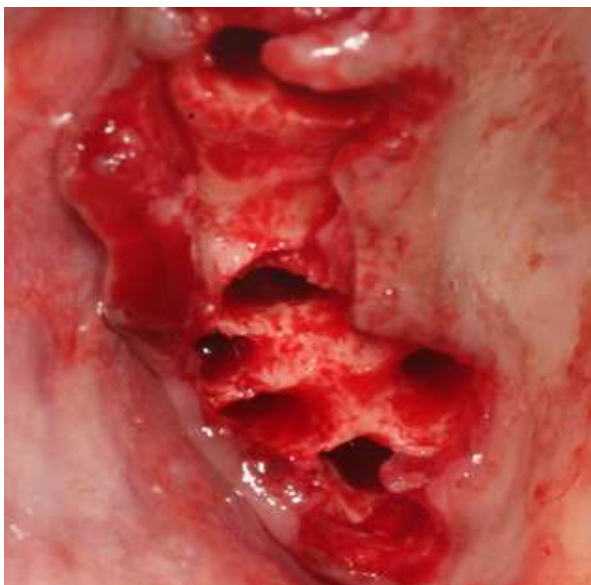
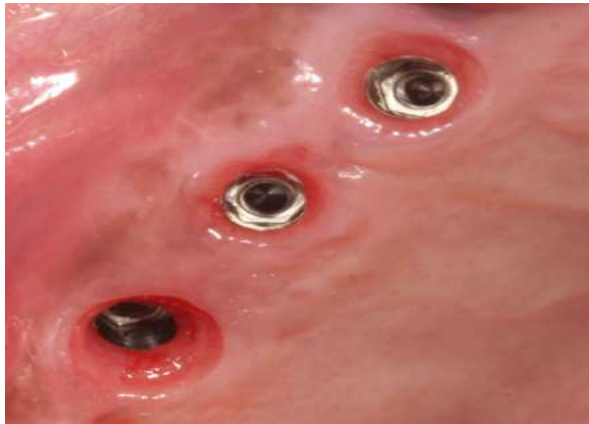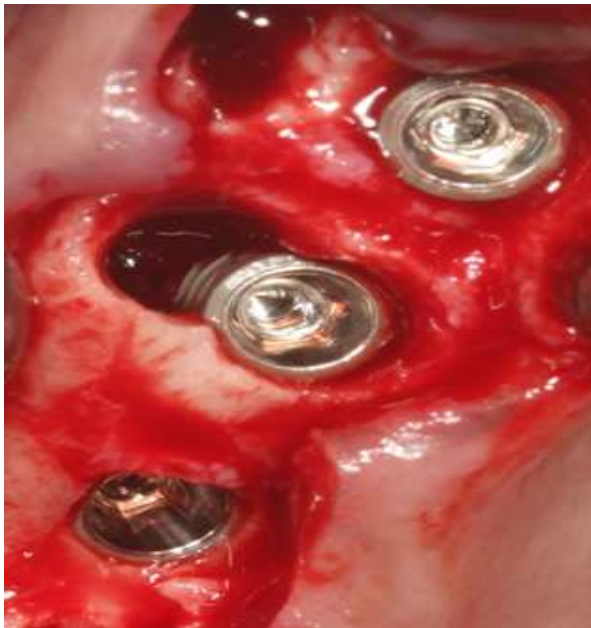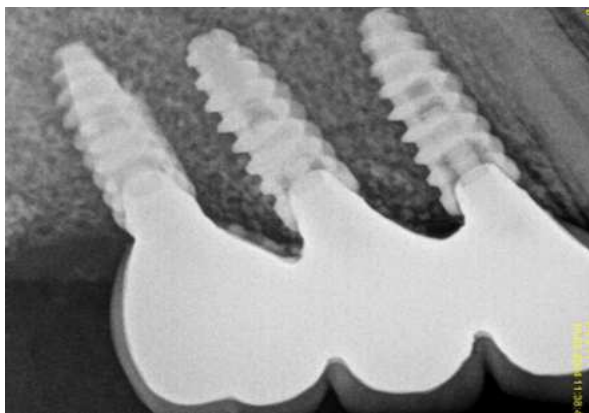
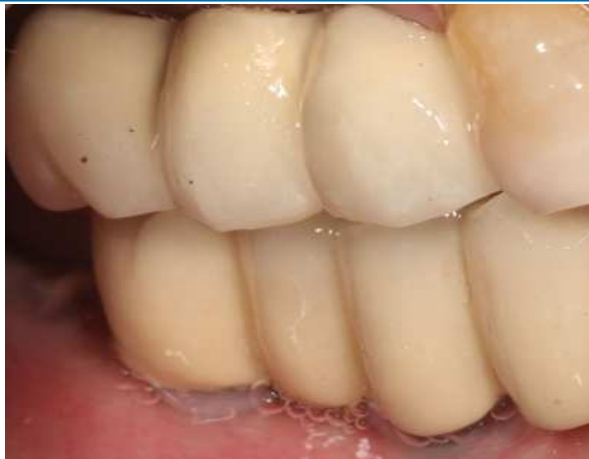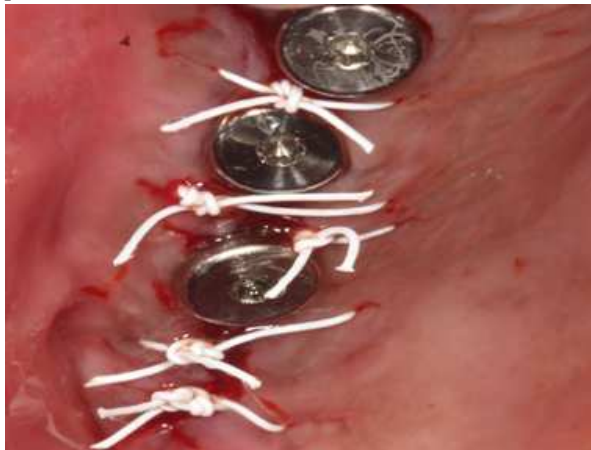There are number of bone grafts available for bone augmentation. Depending on the case the clinic an should decide on the type of bone graft used and the technique used whether it is a single technique or a combination.

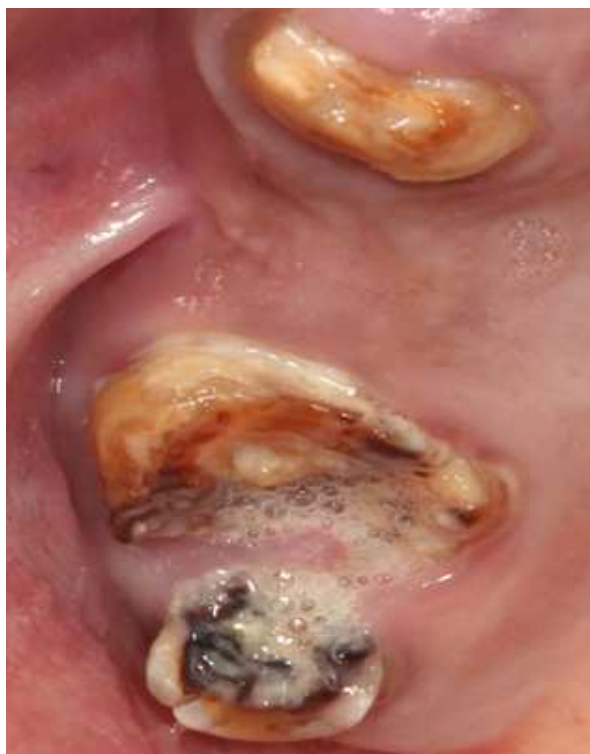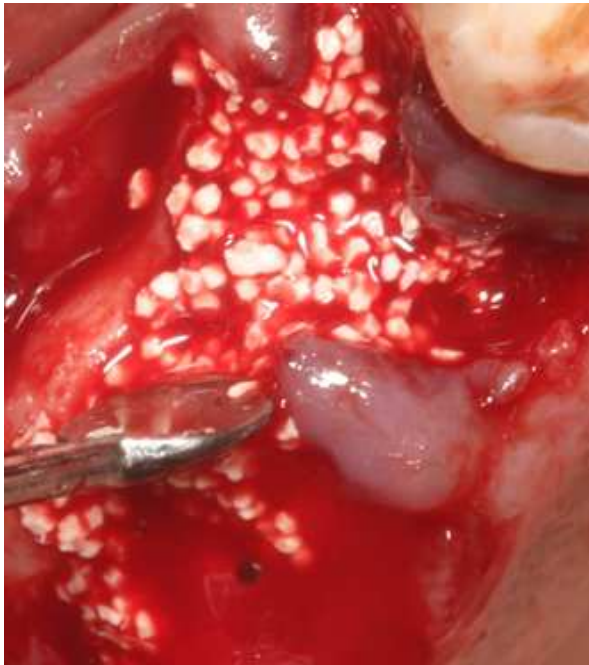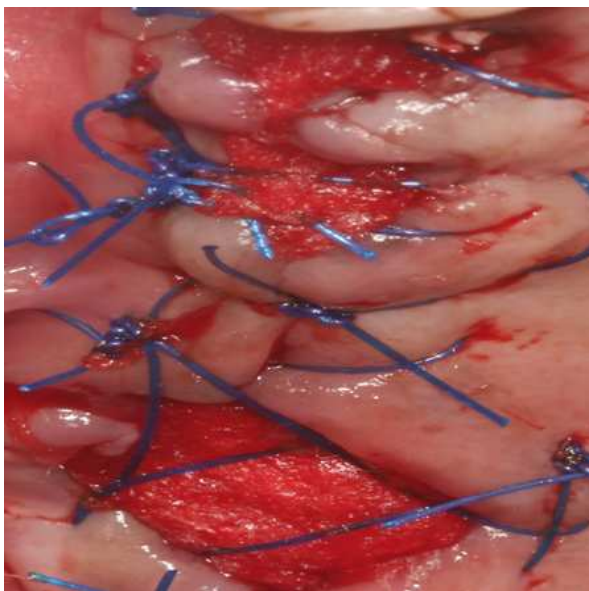
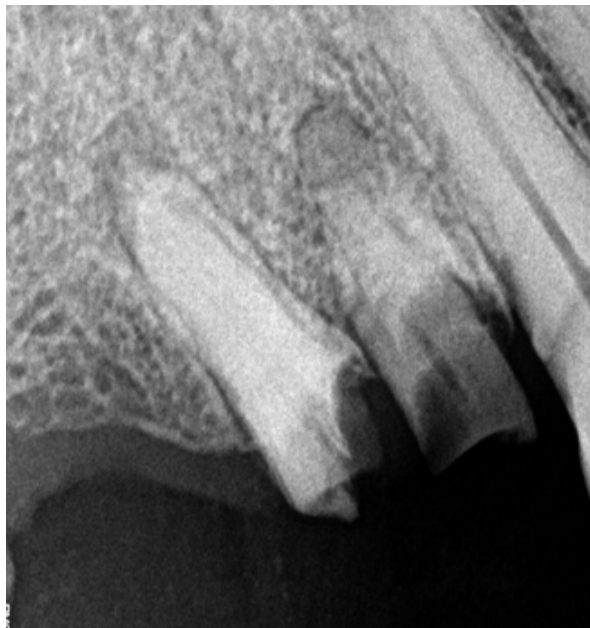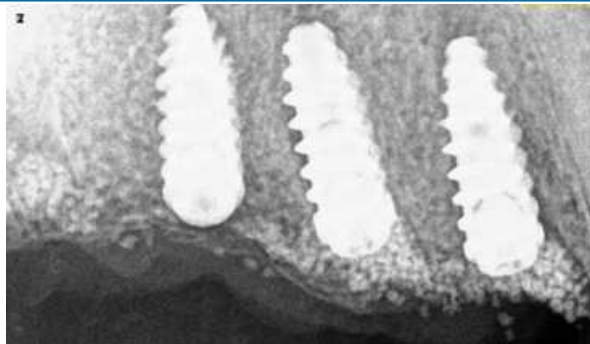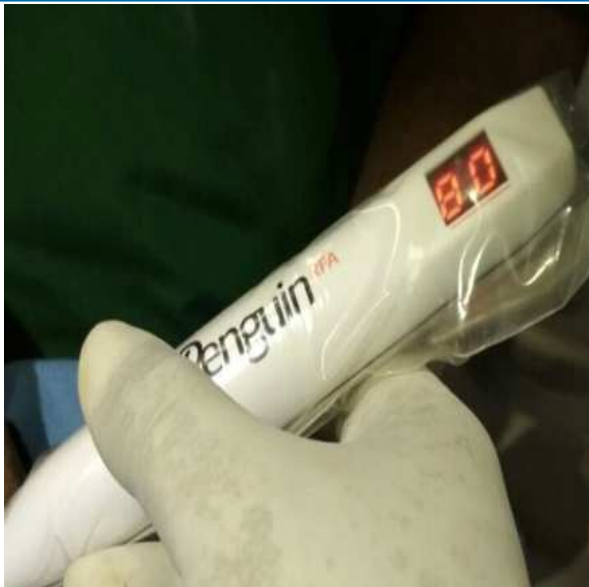While one graft may be favorable for certain case it might not be ideal for another. This depends on the clinician's expertise to choose the right one for a particular case.

However the advantages of using alloplastic bone graft are

that there is unlimited supply, it reduces complexity of surgical procedure by eliminating need for bone harvesting. There are no religious considerations as seen in the case of Xenografts.

Qualy Bone has shown promising results in our clinical practice.





REFERENCES

1. Brighton C, Friedlaender G, Lane J. Bone Formation and Repair. Rosemont, IL: American Academy of Orthopedic Surgeons; 1994: 542.
2. Urist MR. Bone: Formation by autoinduction. Science 1965; 150: 893-899.
3. Tarnow DP, Eskow RN, Zamzok J. Aesthetics and implant dentistry. Periodontol

- 2000 1996; 11:85-94.
4. Pietrokovski J, Massler M. Alveolar ridge resorption following tooth extraction. *J Prosthet Dent* 1967; 17: 21-27.
 5. McAllister BS, Haghighat K. Bone augmentation techniques. *J Periodontol*. 2007 Mar;78(3):377-96. doi:10.1902/jop.2007.060048. PMID:17335361.
 6. Laurencin C, Khan Y, El-Amin SF. Bone graft substitutes. *Expert Rev Med Devices*. 2006;3:49
 7. Bone Augmentation for Implant Placement: Recent Advances
Van Viet Dam, Hai Anh Trinh, Dinesh Rokaya, and Dinh Hai Trinh
2015;2015:19. doi:10.1155/2015/365050.365050
 8. Chiapasco M., Casentini P., Zaniboni M. Bone augmentation procedures in implant dentistry. *The International Journal of Oral & Maxillofacial Implants* . 2009;24:237-259. 8. Deev R. V., Drobyshev A. Y., Bozo I. Y., Isaev A. A. Ordinary and activated bone grafts: applied classification and the main features. *BioMed Research International*
 9. Browaeys H., Bouvry P., De Bruyn H. A literature review on biomaterials in sinus augmentation procedures. *Clinical Implant Dentistry and Related Research* . 2007;9(3):166-177. doi:10.1111/j.1708-8208.2007.00050.x.
 10. Aghaloo T. L., Moy P. K. Which hard tissue augmentation techniques are the most successful in furnishing bony support for implant placement? *The International Journal of Oral & Maxillofacial Implants*. 2007;22:49-70.
 11. Dimitriou R., Jones E., McGonagle D., Giannoudis P. V. Bone regeneration: current concepts and future directions. *BMC Medicine* . 2011;9(1):p. 66. doi: 10.1186/1741-7015-9-66.
 12. Turco, Gianluca & Porrelli, Davide & Marsich, Eleonora & Vecchies, Federica & Lombardi, Teresa & Stacchi, Claudio & Lenarda, Roberto. (2018). Three-Dimensional Bone Substitutes for Oral and Maxillofacial Surgery: Biological and Structural Characterization. 9. 62. 10.3390/jfb9040062.